VOL 7 • NO 1

ePATIENT

NUCLEAR MEDICINE & MOLECULAR IMAGING

THE FREE NUCLEAR MEDICINE & MOLECULAR IMAGING EDUCATIONAL MAGAZINE AVAILABLE WORLDWIDE

NUCLEAR MEDICINE MADE SIMPLE

MÉDECINE NUCLÉAIRE SIMPLIFIÉE

MEDICINA NUCLEAR EN PALABRAS SENCILLAS

核醫學簡單

PANGEA PROJECT

PANGEA

TECHNEGAS™
FUNCTIONAL LUNG IMAGING

BENEFITS
V/Q SPECT TECHNEGAS™

Proven diagnostic accuracy
with high sensitivity and specificity [1]

Minimally invasive
aiding patients's confort and compliance [2]

Detects subsegmental
Pulmonary Embolism (PE) [3]

Low radiation burden
26-36 times less absorbed dose to breast of females [4]

Technegas™ has minimal exclusion criteria and may be administered to most patients[4-6] including:
Renal impaired | Contrast allergy | Diabetics
Chronic Obstructive Pulmonary Disease (COPD) | Critically ill
Pregnant

V/Q SPECT TECHNEGAS™ IN NUCLEAR GUIDELINES

The EANM Guidelines[7] strongly recommend ventilation-perfusion single photon emission computed tomography (V/Q SPECT) as it allows the diagnosis of PE with accuracy even in the presence of COPD and pneumonia.

The CANM Guidelines[8] consider Technegas™ as the agent of choice in COPD population because it has less central airway deposition, better peripheral penetration and it does not wash away quickly as traditional aerosols. Only a few breaths are sufficient to achieve an adequate amount of activity in the lungs, reducing time and personnel exposure.

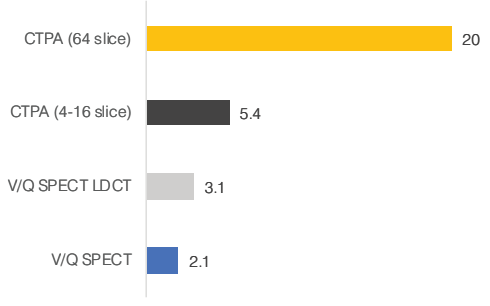

Table 1: Radiation exposure [8] (mSv) (adapted from CANM guidelines, 2018)

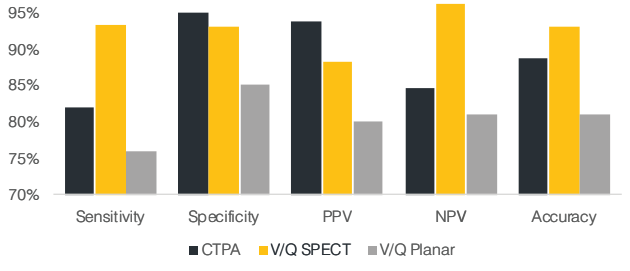

Table 2: Diagnostic ability of CTPA, V/Q SPECT and V/Q Planar to detect PE (adapted from Hess et al, 2016)

All PE's should have a final control 3 months after diagnosis to assess final reperfusion and to benefit from the availability of a baseline exam in case of recurrent symptoms. Low radiation exposure allows repeated studies (*table 1*).

With the uptake in SPECT imaging, V/Q SPECT results are seen as being superior to planar imaging and computed tomography (CTPA) when comparing sensitivity, negative predictive value and accuracy (*table 2*).[1]

Therefore, in situations of acute PE, chronic PE, pregnancy, paediatrics and the COPD population, V/Q SPECT can be considered as a first-line investigation due to its high sensitivity and specificity, low radiation and no adverse reactions.[8]

TO LEARN HOW TO PERFORM A V/Q SPECT STUDY WITH TECHNEGAS™, VISIT: https://bit.ly/2PZDDii

References

1. Hess S, et al. Semin Thromb Hemost 2016; 42: 833–845
2. Sánchez-Crespo A, et al. Nucl Med Commun 2008; 29(2): 173-177
3. Grüning T, et al. Clin Imaging 2014; 38(6): 831-835
4. Isidoro J, et al. Phys Med 2017; 41: 93-96
5. Miles S, et al. Chest 2009; 136: 1546-1553
6. Nasr A, et al. EC Pulmon and Respir Medicine 2017; 4(3): 85-91
7. Bajc M, et al. Eur J Nucl Med Mol Imaging 46, 2429–2451
8. Leblanc M , et al. CANM Guidelines 2018; published Nov 2018

Technegas™ is not yet available for sale in the USA.
Last revision (A4): v.2.1 (14/Apr/2021)
For more information please visit **www.cyclomedica.ca** or email **technegas.sales@cyclomedica.ca**

cyclomedica

Content

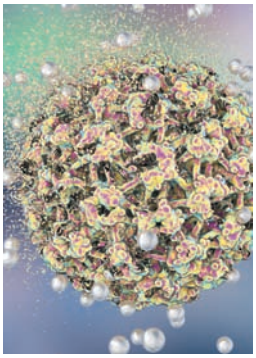

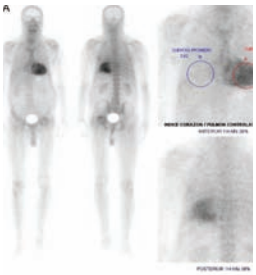



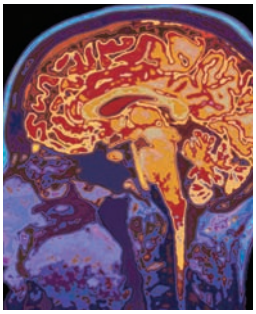

4 EDITORIAL BOARD

5 LES AVANCÉES MÉDICO-PHARMACOLOGIQUES

10 THERANOSTICS : THE MERGING OF DRUG THERAPY AND DIAGNOSTICS TO ADVANCE PERSONALISED MEDICINE.

12 MEDICINA NUCLEAR EN AMILOIDOSIS CARDÍACA

18 INDICATIONS DE LA SCINTIGRAPHIE DE LA VOIE DOPAMINERGIQUE PRÉ-SYNAPTIQUE PAR LE DATSCANTM DANS LE BILAN DES SYNDROMES PARKINSONIENS

25 新型SPECT肺通气灌注三维定量分析在预测肺癌患者肺叶切除术后残余肺功能的临床价值

26 NUCLEAR BRAIN IMAGING IN MEDICAL PRACTICE IN JAPAN

29 WORLD FEDERATION OF NUCLEAR MEDICINE AND BIOLOGY

30 THE CANADIAN ASSOCIATION OF NUCLEAR MEDICINE ASSOCIATION CANADIENNE DE MÉDECINE NUCLÉAIRE

32 FACEBOOK DE L'AMSMNQ AMSMNQ FACEBOOK

33 ASSOCIATION DES MÉDECINS SPÉCIALISTES EN MÉDECINE NUCLÉAIRE DU QUÉBEC

36 POSITRON EMISSION TOMOGRAPHY (PET)

42 APORTE DEL SPECT/CT EN TÉCNICA DEL GANGLIO CENTINELA PARA CÁNCER DE MAMA

44 THERAGNOSTICS: LU-177-PSMA TREATMENT FOR METASTATIC PROSTATE CANCER – CASE EXAMPLES

47 CANM GUIDELINES FOR VENTILATION/PERFUSION (V/P SPECT) IN PULMONARY EMBOLISM

CANM ACMN

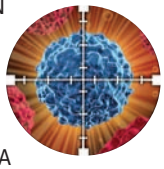

Editors:
Drs. François Lamoureux & Jean-Luc Urbain

Featured in this issue:
Dr. Francois Lamoureux - Dr. Jean-Luc Urbain
Dr. Juan Luis Londono Blair - Dr. Wei He
Dr. Christian Scheiber - Dr. Jun Hatazawa
Dr. René Fernández - Dr. Éric Turcotte
Dr. Rodrigo Jaimovich - Dr. Kalevi Kairemo

Publication Director:
Nicolas Rondeau Lapierre

Publisher:
Les Éditions Multi-Concept inc.

Artistic direction and printing:
Le Groupe Communimédia inc.

Advertisement information:
Nicolas Rondeau Lapierre
514-331-0661 #132
nlapierre@editionsmulticoncept.com

The ePatient magazine is published quarterly by the publishing company, Les Éditions Multi-Concept Inc. 1600 Henri-Bourassa Blvd West, Suite 405, Montreal, Quebec, H3M 3E2

Secretarial office:
Tel.: (514) 331-0661
Fax: (514) 331-8821
Email : nmpangeaproject@gmail.com

Legal Deposit:
Library and Archives Canada
Library and Archives Canada

Post-Publication Agreement
No. 40011180

Subscription information:
Quarterly publication, nmpangea.com

Financé par le gouvernement du Canada | Canada

SUBSCRIBE HERE ! INSCRIVEZ-VOUS ICI !
SUSCRÍBETE AQUÍ ! 在这里签名! in your own language !

Don't miss our next issue on Quantification and the second part of Theranostics (neuroendocrine tumors).

EDITORIAL BOARD

I am thrilled to introduce our outstanding editorial board members. Through our travel and NM lecturing around the globe, I have met terrific scientists and colleagues. Most, if not all of them, are really passionate about and true advocates for the field of nuclear medicine. They strongly believe in the power, usefulness and safe use of NM diagnostic and therapeutic procedures for the betterment of public healthcare worldwide. I am delighted that the following leaders have embraced the concept of the Pangea-ePatient magazine and accepted to share their invaluable expertise and experience with patients, referring colleagues, health care administrators, government agencies and insurance companies.

Dr. François Lamoureux
Dr. Jean-Luc Urbain

Dr. François Lamoureux,
M.D.,M.Sc., FRCPSC,
President, CANM, Canada

Dr. Jean-Luc Urbain,
M.D., Ph.D., CPE, FASNC
President 2021-2022 WFNMB
Past President, CANM, Canada

Dr. Akram Al-Ibraheem, M.D.
President, Arab Society of Nuclear Medicine (ARSNM)
Chairman, Department of Nuclear Medicine & PET/CT
King Hussein Cancer Center, Amman, Jordan

Dr. Zvi Bar-Sever, M.D.,
Chair Pediatric Nuclear Medicine Council,
EANM; Director, Institute
Schneider Children's Hospital, Israel

Dr. Paige Bennett, M.D.,
Nuclear Medicine/Medical Imaging
Specialist, Wake Forest University,
USA

Dr. Salah-Eddine Bouyoucef, M.D.,
Ph.D., Chief Nuclear Medicine,
CHU Bab El Oued, Alger, Algeria

Dr. Sanjay Gambhir, M.D., Ph.D.,
Chief/Chair, Nuclear Medicine,
University of Lucknow, India

Dr. Bennett Greenspan, M.D.,
Past President of the SNMMI, USA

Dr. Mohamad Haider, M.D.
Vice-President, Arab Society of Nuclear Medicine (ARSNM)
Director, Nuclear Medicine Division and Cyclotron Facility
American University of Beirut Medical Center, Beirut, Lebanon

Dr. Jun Hatazawa, M.D., Ph.D.,
Past President of the AOFNMB,
Japan

Dr. Wei He, M.D., Ph. D.,
Director of Nuclear Medicine and
PET/CT, Center Fu Dan University,
China

Dr. Rodrigo Jaimovich, M.D
Past-President of ALASBIMN
Professor, Nuclear Medicine
at Clinica las Condes S.A
Chili University, Chili

Dr. Fernando Mutt, M.D.,
Past President ALASBIMN, Uruguay

Dr. Andrew Ross
Past President, CANM

Dr. Raymond Russel, M.D., Ph.D.,
Past President, CANM, Canada
Associate Professor of Medicine Warren Alpert
Medical School of Brown University, Director,
Nuclear Cardiology, Rhode Island Hospital &
Past President, American Society of Nuclear Cardiology

Dr. Einat Sapir, M.D., Ph.D.,
Professor, Sackler School of Medicine,
Tel Aviv University & Head,
Department of Nuclear Medicine
Tel Aviv Sourasky Medical Center, Israel

Dr. Mike Sathekge, M.D., Prof.,
University of Pretoria, Head of
Nuclear Medicine Steve Biko Acad-
emic Hospital & President, Colleges of
Medicine of South Africa, South Africa

Dr. Christian Sheiber, M.D., Ph.D.
Professor and Chief of Nuclear
Medicine, Hospitals de Lyon, France

Dr. Andrew Scott, M.D.,
Past President WFNMB,
Australia

Dr. Jean-Philippe Vuillez,
M.D.,Ph.D., Prof.,
Ancien président SFMN
Vice-Doyen Formation Directeur des
études PU-PH – Médecine Nucléaire,
France

Dr. Nadia Whithofs,
M.D., Ph.D,
Division of Nuclear Medicine
and Oncological Imaging,
CHU of Liege, Belgium

Dr Jolanta Kunikowska MD,PhD
Associate professor of nuclear
medicine department, Medical
University Warsaw Poland
President EANM

LES AVANCÉES MÉDICO-PHARMACOLOGIQUES

François Lamoureux,
M.D, M.Sc., FRCPC

L'HIVER NUCLÉAIRE

L'Énergie Nucléaire procure à l'être humain des avantages énormes et lui rend la vie plus sécuritaire et plus performante.

ON VIT EN CONSTANCE PRÉSENCE DE CETTE ÉNERGIE.

Par exemple, la plupart des détecteurs de fumée dans nos maisons possèdent un composant radioactif, l'Américium 241 (demi-vie 470 années). Dans notre corps, nous avons une minime quantité de Potassium 40 (demi-vie 1.248 milliard d'années) ou de Carbone 14 (demi-vie 5730 années). Dans plusieurs sous-sols de maisons, on retrouve le gaz radioactif Radon 222 (demi-vie 3.8 jours) : son exposition répétée et sur une longue période de temps peut engendrer un cancer du poumon. On estime qu'au Canada, le Radon serait la deuxième cause principale du cancer du poumon après le tabagisme, soit 18 pour cent des cas. C'est pourquoi il faut bien ventiler ses sous-sols.

Un autre exemple de l'apport de l'Énergie Nucléaire, les grandes puissances utilisent l'Énergie Nucléaire pour produire de l'électricité ou pour assurer le mouvement de leurs énormes porte-avions ou encore leurs sous-marins. Ces derniers, grâce à leurs moteurs à Énergie Nucléaire, peuvent demeurer sous l'eau des mois sans remonter à la surface, alors que les sous-marins mus au diesel, par exemple, ne demeurent habituellement sous l'eau que pour une durée de 24 heures. Les sous-marins nucléaires peuvent donc demeurer à l'affût pendant des mois sous la calotte glaciaire de l'Antarctique ou de l'Arctique.

Mais l'être humain utilise aussi cette Énergie Nucléaire pour construire des armes de destruction massive, LES BOMBES ATOMIQUES.

Aujourd'hui, certaines de ces bombes peuvent dépasser en puissance plus de 50 fois celle des 2 bombes atomiques qui ont été larguées sur Hiroshima et Nagasaki en 1945, causant immédiatement plus de 75 000 morts dans chacune de ces villes. Par la suite, plusieurs milliers d'autres morts sont survenues conséquemment aux radiations émises.

Aujourd'hui, plusieurs pays possèdent, à diverses puissances, ces bombes. Un conflit nucléaire risque en totalité ou en grande partie la survie de l'espèce humaine. On croit qu'un jour, une météorite a frappé la Terre et que les dinosaures ont disparus. Est-ce que cela serait la même issue pour l'espèce humaine en cas de conflit nucléaire? Cette

éventualité donne froid dans le dos car on vivrait ce que d'aucuns appellent L'HIVER NUCLÉAIRE.

En effet, les nouvelles bombes nucléaires larguées pourraient immédiatement détruire une ville entière sur des dizaines de kilomètres et tuer l'ensemble de ses habitants et de ses animaux. La couche d'ozone serait immédiatement affectée, les rayons ultra-violets seraient délétères, un refroidissement s'installerait en raison des débris atmosphériques et il s'en suivrait une perte de la luminescence. Pire encore, la Terre subirait une pluie et une suie radioactives composées de toxiques éléments radioactifs comme l'Iode 131 (demi-vie 8,01Jours), le Césium 137 (demi-vie 30,2 années), le Strontium 90 (demi-vie 28,8 années), le Césium 134 (demi-vie 2,06 années), le Zirconium 95 (demi-vie 64,02 jours) et le Ruthénium 106 (demi-vie 373 jours) pour n'en nommer que quelques-uns. Les sols, les végétaux, la faune et la flore seraient détruits ou contaminés radioactivement, rendant leur contact, inhalation ou ingestion extrêmement délétères.

Pour les survivants en sursis de survie temporaire, ils seraient victimes de blessures sévères, de malformations et irrémédiablement de cancers. La famine universelle s'installerait.

UNE GUERRE NUCLÉAIRE GLOBALE, C'EST LA FIN DE L'ÊTRE HUMAIN. LES QUELQUES HUMAINS QUI SURVIVRAIENT SERAIENT EN QUELQUE SORTE DES ZOMBIES RADIOACTIFS EN ATTENTE D'UNE MORT PRÉCOCE.

Malheureusement, l'homme serait responsable de sa propre disparition, contrairement aux dinosaures qui eux ne se sont pas autodétruits. L'être humain, lui, pourrait le faire.

D'aucuns pourraient arguer qu'un conflit nucléaire pourrait être régionalement limité par l'utilisation de bombes nucléaires de puissance limitée.

Mais ce scénario, dans notre monde actuel, est difficilement envisageable. Une réaction en chaîne et de plus en plus meurtrière et étendue risque d'être le vrai scénario.

Je sais, c'est une vision catastrophique. Il faut se rappeler que plusieurs pays possèdent ces armes de destruction massive :

Les États-Unis, plus de 5 000 ; L'URSS, plus de 5 000 ; La France, Le Pakistan, La Corée du Nord, l'Israël, le Royaume-Uni, la Chine et l'Inde, quelques centaines ou dizaines de ces armes atomiques.

L'histoire de l'Homme depuis son arrivée sur la Terre est une succession de guerres fratricides et destructrices. Nous avons un léger répit depuis 80 années, mais pour combien de temps encore?

Nous, médecins et technologues nucléaires, utilisons au jour le jour cette formidable énergie pour le plus grand bénéfice de nos patients. Nous réalisons aussi l'immense danger pour la survie de l'être humain lorsque cette Énergie Nucléaire se retrouve entre des mains imprévisibles. ■

MEDICAL AND PHARMACOLOGICAL ADVANCES

François Lamoureux,
M.D, M.Sc., FRCPC

THE NUCLEAR WINTER

Nuclear Energy provides enormous benefits to human beings and makes their life more safer and more efficient.

WE LIVE IN THE CONSTANT PRESENCE OF THIS ENERGY.

For example, most smoke detectors in our homes have a radioactive component, Americium 241 (half-life 470 years). In our body we have a minimal quantity of Potassium 40 (half-life 1.248 billion years) or Carbon 14 (half-life 5730 years). In several basements of houses, there is a radioactive gas called Radon 222 (half-life 3.8 days) and its repeated exposure over a long period of time can cause lung cancer. It is estimated that in Canada, Radon would be responsible for the second cause lung cancer, after smoking, with 18 percent of cases. It is necessary to ventilate its sub-floors.

Another example of the contribution of Nuclear Energy, the great powers use Energy nuclear to produce electricity or to ensure the movement of their enormous carriers, planes or even their submarines. All of this is possible due to their Nuclear Energy engines that can remain underwater for months without coming to the surface while submarines diesel engines, for example, usually only remain underwater for 24 hours. Nuclear submarines can therefore remain on the lookout, months under the Antarctic or Arctic ice sheet.

But the human being also uses this Nuclear Energy to build weapons of mass destruction, the ATOMIC BOMBS.

Today the newer models can exceed in power more than 50 times the energy produced with the 2 atomic bombs that were dropped on Hiroshima and Nagasaki in 1945, immediately causing more than 75,000 deaths in each of these cities. Subsequently thousands and thousands of other deaths from the consequences of the radiation emitted. Today several countries have these bombs in various powers. A large or small nuclear conflict could threaten the survival of the human species. We believe that the dinosaurs disappeared because a meteorite hit the earth and vaporized the entire species. What about human in the event of a nuclear conflict?

This eventuality sends shivers down the spine because we would experience what some call **THE NUCLEAR WINTER.**

Indeed the new nuclear bombs dropped could immediately destroy a city over tens of kilometres and kill all of its inhabitants and animals. The ozone layer would be immediately affected, ultraviolet rays will be harmful, a cooling temperature would settle due to atmospheric debris and there would be a loss of luminescence. Worse still, the earth would experience radioactive rain and soot composed of toxic radioactive elements such as Iodine 131 (half-life 8.01 days), Cesium 137 (half-life 30.2 years), Strontium 90 (half-life 28.8 years), Cesium 134 (half-life 2.06 years), Zirconium 95 (half-life 64.02 days) and Ruthenium 106 (half-life 373 days) to name a few and only a few.

The soils, plants, fauna and flora would be either destroyed or contaminated radioactively making their contact, inhalation or ingestion extremely harmful. For survivors on temporary survival, they will be victims of severe injuries, malformations and irremediably cancers. Universal starvation will set in.

A global nuclear war is the end of human beings. The few humans who would survive would be some sort of radioactive zombies waiting on the final doomsday.

Unfortunately, the man would be responsible for his own disappearance contrary to the dinosaurs that did not self-destruct. Humans could do it.

Some might argue that a nuclear conflict could be regionally limited by the use of nuclear bombs of limited power. But this scenario in our current world is difficult to imagine. A reaction in chains and increasingly deadly and extensive may be the real scenario.

I know it's a catastrophic vision. It should be remembered that several countries have these weapons of mass destruction:

USA more than 5000, USSR more than 5000, France, Pakistan, North Korea, Israel, the United Kingdom, China and India a few hundred or dozens of these atomic weapons.

The history of man since his arrival on earth is a succession of fratricidal wars and destructive behaviour.

We, nuclear physicians and technologists, use this tremendous energy on a daily basis for the greater benefit of our patients. We also realize the immense danger to the survival of the human being when this Nuclear Energy. ■

ISOLOGIC
Radiopharmaceutiques Novateurs

Soins de qualité fiable

illuccix®

Maintenant Disponible

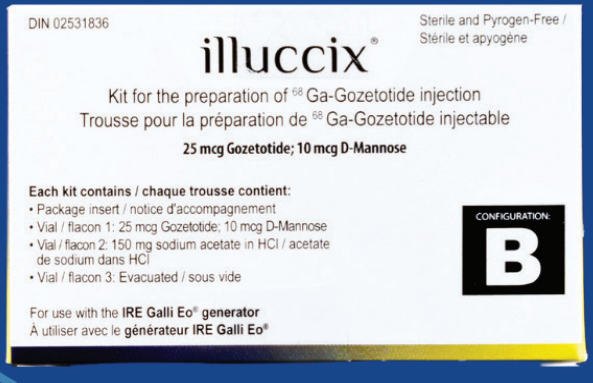

Trousse pour la préparation de ^{68}Ga-Gozetotide injectable

ISOLOGIC Radiopharmaceutiques Novateurs distributeur de l'agent d'imagerie du cancer de la prostate Illuccix®, également connu sous le nom PSMA-11

Élargir notre offre de produits radiopharmaceutiques avec Illuccix® la trousse de préparation de ^{68}Ga PSMA-11 s'inscrit dans la continuité de notre mission d'améliorer la santé des Canadiens, en leur assurant l'accès à des produits TEP afin d'aider les médecins à diagnostiquer des maladies comme le cancer.

DORVAL (siège social)
11215, Ch. de la Côte-de-Liesse
Dorval QC H9P 1B1
514 636.4711

MONTRÉAL
1855, 32e Avenue
Lachine QC H8T 3J1
514 636.5552

VILLE DE QUÉBEC
2655, rue Dalton
Québec QC G1P 3S8
418 650.1855

TORONTO
Hôpital Sunnybrook
2075, Bayview Avenue
Toronto ON M4N 3M5
416 480.6100

OTTAWA
1053, Carling Avenue
Bureau F156
Ottawa ON K1Y 4E9
613 761.5370

BURLINGTON
5450, Harvester Road
Burlington ON L7L 5N5
905 333.1789

VANCOUVER
899, West 12th Avenue
Vancouver C.-B. V5Z 1M9
604 875.5085

info@isologicradiopharm.ca
isologicradiopharm.ca
Suivez-nous !

Jean-Luc Urbain
M.D., Ph.D., CPE
Past President, CANM

THERANOSTICS SERIES:

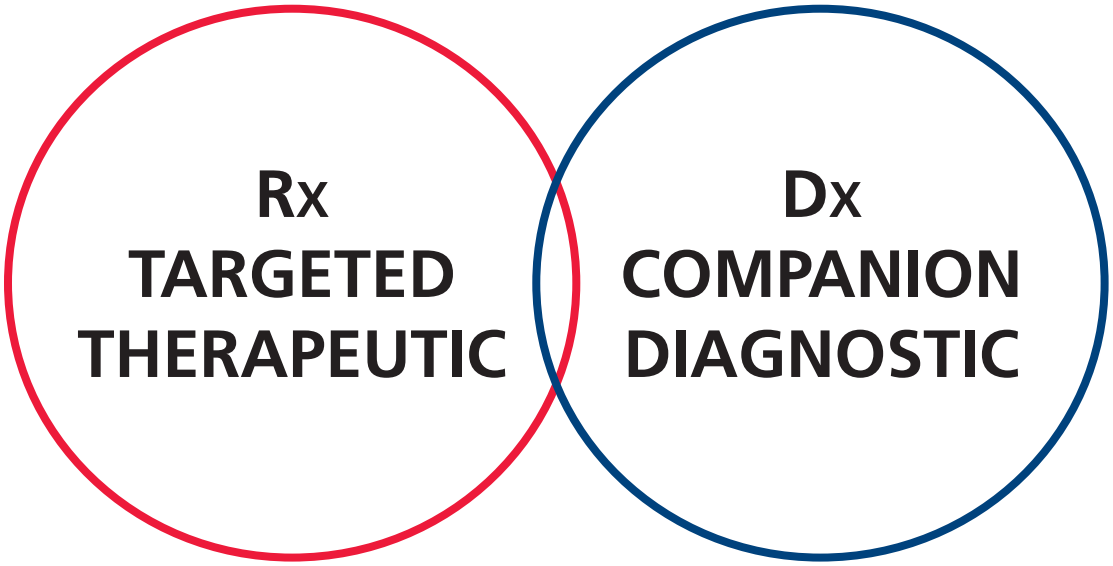

THERANOSTICS

The merging of drug therapy and diagnostics to advance personalised medicine

INTRODUCTION:

In the second issue of our magazine we described the therapeutic use of Iodine, the first true Theranostics compound available. In this edition of our magazine we will put the emphasis on the most recent developments in the utilization of medical isotopes for therapy of cancers

The modern landmark for Theranostic nuclear medicine originated in the seventies with the discovery of Somatostatin. Somatostatin, a 14-amino acid Cystin bridge-containing peptide, was first discovered in 1973. The elucidation of its three dimensional structure, its metabolism and biological activity site in the following years rapidly lead to the synthesis of a large number of analogs. Identified as the most stable and active in inhibiting the effect of the growth hormone, Octreotide, one of the derivatives, demonstrated enough in vivo stability to obtain regulatory approval in 1988 for the treatment of acromegaly and carcinoid tumors.

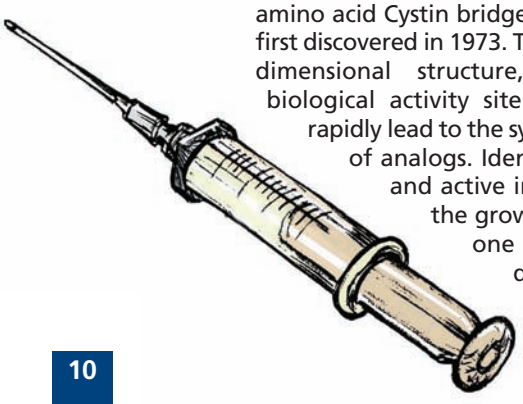

The coupling of Octreotide to gamma emitting isotopes in the late 80's and early 90's represented a major breakthrough to what we now call molecular targeted imaging. Furthermore it's labeling with yttrium 90 and lutetium 177 in the early 2000's started the modern era of theranostic nuclear medicine by introducing the fast growing field of peptide receptor radionuclide therapy (PRRT). In PRRT, specific receptors present at the surface of tumors can now be detected, imaged, treated and followed up with the same peptidomimetic labeled with either imaging or killer isotopes. Labeled with gallium 68, a positron emitter and lutetium 177 a gamma and beta emitter, the somatostatin analog dotatate has recently emerged as a prime tool to diagnose, treat and follow up the treatment's efficacy of neuroendocrine tumors overexpressing the somatostatin receptor.

Tagged with bifunctional chelating agents, native peptides, hormones, neurotransmitters and peptidomimetics are now emerging as suitable molecules for site-directed targeted imaging and therapy. Among the most promising of these compounds in nuclear medicine are the inhibitors of the prostate specific membrane antigen (PSMA).

PSMA is a cell membrane receptor which is significantly over-expressed in prostate cancers. Its expression increases with tumor aggressiveness, androgen-independence, metastatic disease, and disease recurrence. Evidence suggests that PSMA may perform multiple physiological functions within the cell: a role in signal transduction, cell migration, receptor function for an unidentified ligand and nutrient uptake such as glutamate and folate have been suggested.

Having a sensitive and specific biomarker to localize primary and metastatic prostate cancer would greatly improve the algorithm for the diagnosis and management of prostate cancer. Other than skin cancer, prostate cancer is the most common cancer in North America. About one out of seven men in the US will be diagnosed from prostate cancer during his lifetime.

Since 2012, the number of PSMA clinical studies using has exponentially increased. Among these agents, the 68Ga- and 18F-labeled compounds have attracted the most attention, as these compounds can be used for PET/CT imaging. However, the availability of 123I or 99mTc also will allow SPECT/CT imaging in centers without facilities for PET.

Based on these studies, the promising uses of imaging with labeled PSMA ligands in the management of prostate carcinoma include: the primary staging of high risk cancer disease, the biochemical recurrence with low PSA levels (as low as 0.2 ng/ml), identification of lesions for biopsy targeting after negative previous biopsy, the monitoring of systemic treatment in metastatic disease, the active surveillance and the treatment monitoring after 177Lu-PSMA ligand therapy. ■

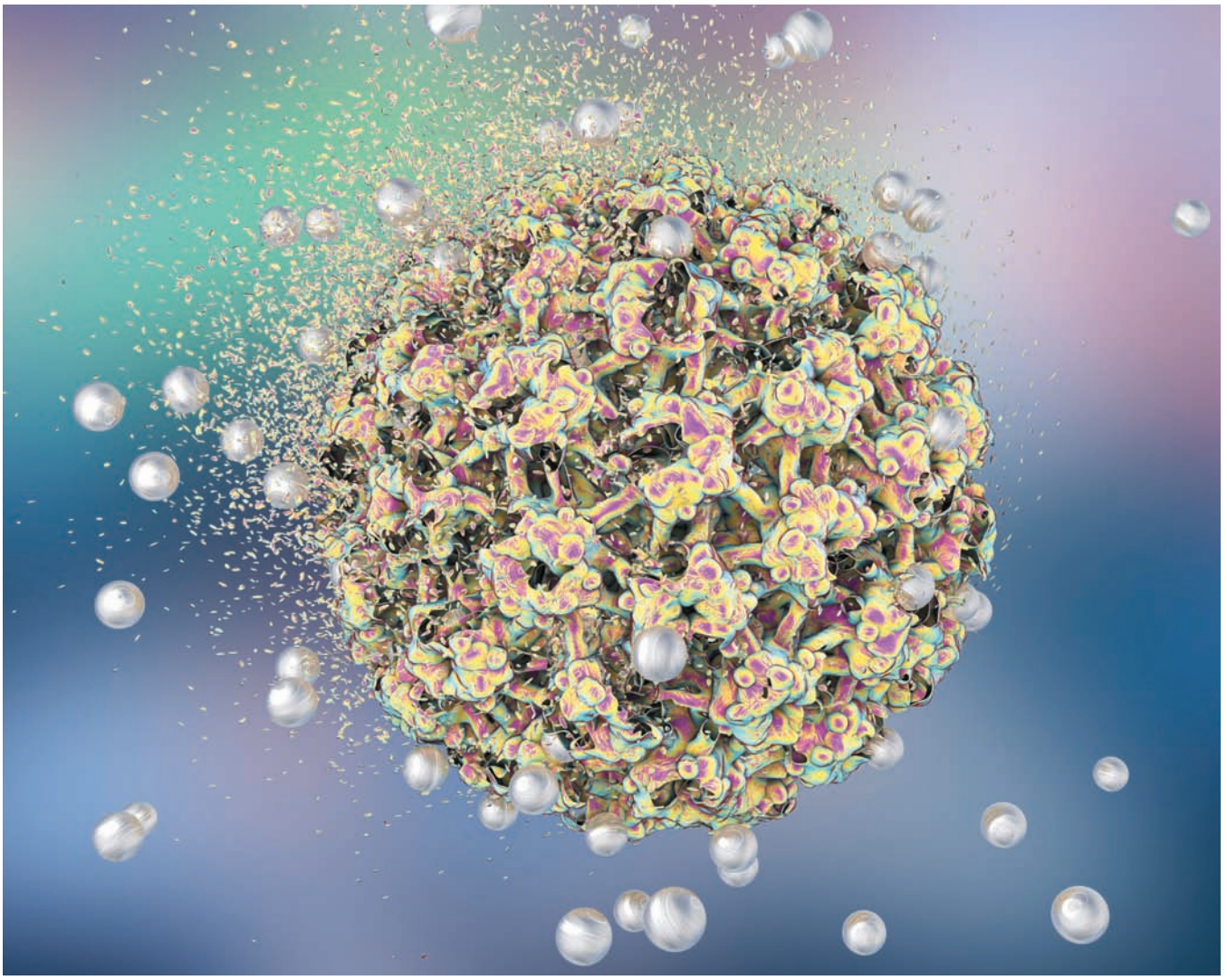

Juan Luis Londoño Blair
Médico Nuclear
Jefe servicio Medicina Nuclear
San Vicente Fundación
Hospital Universitario
Columbia
South América

MEDICINA NUCLEAR EN AMILOIDOSIS CARDÍACA

La Amiloidosis es una enfermedad sistémica en la cual se depositan fibrillas insolubles en varios órganos a nivel extracelular, fibrillas que están compuestas de proteínas que tienen un plegamiento anormal. Frecuentemente, la Amiloidosis compromete el corazón, produciendo Amiloidosis Cardíaca (AC), la cual es una de las formas de falla cardíaca progresiva más comunes. En el tejido cardíaco generalmente se comprometen estructuras como las aurículas y ventrículos, las válvulas, vasos pequeños y el sistema de conducción cardíaco, lo cual produce disfunción sistólica y diastólica, arritmias, bloqueos de conducción y falla cardíaca. Esta entidad causante de falla cardíaca es subestimada en muchos pacientes.

El diagnóstico de amiloidosis cardíaca (AC) frecuentemente se demora, por sus manifestaciones clínicas variadas, y dado que los valores de los biomarcadores cardíacos no son específicos, por la poca sospecha clínica de esta enfermedad y por la disponibilidad hasta hace poco de técnicas específicas para su diagnóstico. El tratamiento selectivo también se retarda en estos pacientes por el diagnóstico tardío de la enfermedad.

La AC tiene dos tipos: la amiloidosis de cadenas livianas (AL) y la Amiloidosis Transtiretina (ATTR). La Amiloidosis Transtiretina se puede dividir a su vez en el tipo "salvaje" o Amiloidosis senil y una forma hereditaria con depósitos de Transtiretina mutante. En la Amiloidosis tipo AL, las fibrillas de amiloide se derivan de las cadenas livianas de inmunoglobulina, producidas por una alteración en las células plasmáticas, mientras que en el tipo ATTR se forman a partir de la proteína transtiretina producida en el hígado.

En la Amiloidosis de tipo AL, el compromiso cardíaco es la principal causa de mortalidad (en un 50% de los pacientes) ocasionada por pérdida acelerada de la función contráctil que progresa desde una falla cardíaca con función ventricular preservada hasta una falla cardíaca con fracción de eyección reducida. La AC tiene una sobrevida promedio si no se trata, de menos de 6 meses para el tipo AL y de 3 a 5 años si es amiloidosis de ATTR.

La identificación del tipo de amiloide cardíaco es un verdadero reto y presenta implicaciones en el tratamiento y en el pronóstico de los pacientes. Hasta hace poco, la AC se podía diagnosticar solamente mediante una biopsia endomiocárdica

o con una combinación de biopsia extracardíaca con una ecocardiografía con hallazgos de espesor de la pared del ventrículo izquierdo mayor de 12 mm, sin alguna causa que explicase este hallazgo. Actualmente la biopsia endomiocárdica se reserva para casos equívocos o en pacientes con hallazgos discordantes entre el cuadro clínico y las imágenes.

Importancia del diagnóstico temprano y preciso en AC

Los síntomas de la enfermedad cardíaca por amiloidosis generalmente son inespecíficos y dada la heterogeneidad de su presentación cardíaca, con los diversos subtipos y con las nuevas opciones terapéuticas que están apareciendo en el mercado, se requiere de una técnica de diagnóstico eficaz, rápida y precisa para el tratamiento oportuno de los pacientes.

El compromiso cardíaco por amiloidosis de tipo AL predispone a eventos cardíacos adversos importantes. Las imágenes cardíacas en AC tienen la ventaja de identificar pacientes con AL, que tienen alto riesgo de mortalidad y pueden orientar en la elección del tratamiento con agentes para quimioterapia usados de forma temprana. Por el contrario, si se identifica AC de tipo ATTR se puede iniciar de forma oportuna el tratamiento con medicamentos antiamiloides. Por esto, la identificación temprana del compromiso cardíaco en amiloidosis y su caracterización en los tipos AL o ATTR es de vital importancia para instaurar de forma adecuada y oportuna el tratamiento.

Imágenes de Amiloidosis Cardíaca con Medicina Nuclear

La biopsia endomiocárdica es específica y hasta hace poco era la prueba patrón de referencia para el diagnóstico de AC. Sin embargo, su naturaleza invasiva limita su realización como prueba de tamizaje temprano. La tendencia actual es a la realización de pruebas no invasivas y más específicas para caracterizar el compromiso cardíaco en la amiloidosis. La Resonancia Magnética Cardíaca (RMC) con contraste con Gadolinio y mapeo en secuencia T1 tiene una alta resolución, provee imágenes cuantitativas y una adecuada caracterización tisular; sin embargo, aún no está ampliamente disponible, requiere mucha experiencia en su interpretación y puede estar contraindicada en algunos pacientes. Adicionalmente, su utilidad en la diferenciación de los tipos de amiloidosis cardíaca es controversial.

Las imágenes de AC con Medicina Nuclear tienen ventajas importantes: están ampliamente disponibles; no son invasivas, permiten hacer cuantificación, permiten hacer imágenes de todo el corazón para valorar la carga de amiloide y se pueden realizar de forma seriada para valorar la respuesta al tratamiento.

Las imágenes con radioisótopos tienen un papel importante en la valoración de la AC. Actualmente

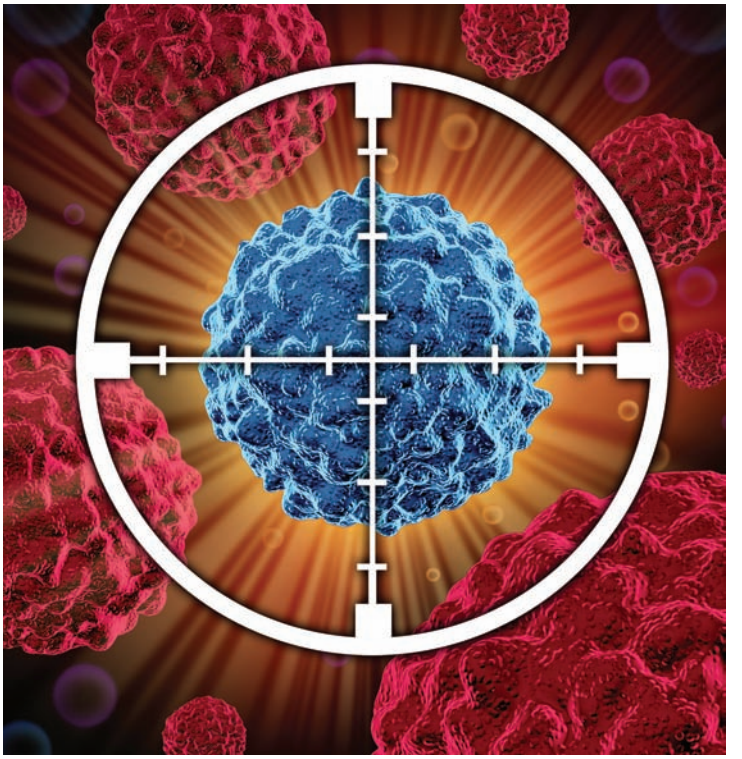

pueden realizarse varios tipos de imágenes, desde imágenes de la inervación simpática del miocardio; imágenes de perfusión miocárdica hasta imágenes del metabolismo e imágenes de los depósitos de amiloide. La gamagrafía con agentes para la valoración del sistema óseo, utilizando el isótopo radioactivo Tecnecio-99m (^{99}mTc) como el 3,3- ácido difosfo-1,2-propanodicarboxílico (^{99}mTc-DPD), Pirofosfato (^{99}mTc-PYP) y el Hidroximetilen Difosfonato (^{99}mTc-HMDP) han demostrado una buena sensibilidad y especificidad para el diagnóstico de ATTR, permitiendo diferenciar el tipo de AC y proveen un diagnóstico temprano no invasivo en la valoración inicial y en el monitoreo seriado para la valoración de la respuesta al tratamiento. Estos agentes tienen una buena eficacia para el diagnóstico de AC de tipo ATTR, permitiendo hacer el diagnóstico diferencial entre ATTR y AL. La sensibilidad varía entre un 83 a un 100% (con un valor promedio estimado en 92.2%) y la especificidad varía de un 67 a un 100% (con un promedio estimado en 95.4%).

Aunque el mecanismo exacto de la acumulación de los radiofármacos para el sistema óseo en la AC tipo ATTR no está claro, se postula que puede deberse a los iones de calcio; a algunos metales presentes y/o a los grupos sulfidrilo del amiloide ATTR.

Los radiofármacos para gamagrafía ósea tiene mejor valor que otras técnicas imagenológicas como la ecocardiografía y la RMC ya que la gamagrafía permite diferenciar la AC de tipo ATTR de otras formas de enfermedad cardíaca con engrosamiento de la pared ventricular. Sin embargo, la técnica gamagráfica carece de información estructural y hemodinámica, por lo

tanto, la gamagrafía puede usarse en conjunto con la Ecocardiografía y la RMC para un mejor diagnóstico.

El uso de la gamagrafía cardíaca con trazadores óseos en el tamizaje de AC en poblaciones específicas, obtiene resultados importantes: permite diagnosticar AC de tipo ATTR en el 14% de pacientes hospitalizados con falla cardíaca con fracción de eyección preservada; en un 16% de los pacientes que van a ser sometidos a reemplazo valvular aórtico transcatéter y en el 10% de los pacientes con síndrome del túnel del canal del carpo.

Trazadores óseos

^{99}mTc-DPD: es uno de los radiotrazadores más estudiados para las imágenes de AC. Sin embargo, su disponibilidad es limitada y su uso casi que limitado a Europa. Este radiotrazador tiene una alta sensibilidad, cercana al 100%, mayor que la de la ecocardiografía o de la RMC y una especificidad del 100% en el diagnóstico diferencial de ATTR versus AL. Permite estimar la carga de amiloide cardíaco y predice el riesgo de hospitalización por falla cardíaca. También permite detectar captación en los tejidos blandos mediante la realización de gamagrafía de cuerpo entero con mayor sensibilidad que con otros radiotrazadores.

^{99}mTc-HMDP: ha mostrado eficacia diagnóstica cercana a los otros radiotrazadores para el estudio de la AC.

^{99}mTc-PYP: es el único radiotrazador óseo aprobado para uso clínico en amiloidosis en Estados Unidos.

Trazadores de inervación cardíaca

Los pacientes con Amiloidosis tienden a desarrollar disautonomía cardíaca que puede estar causada por infiltración de amiloide en el tejido de conducción cardíaco, tanto en ATTR como en AL. El trazador Metayodobencil Guanidina marcado con yodo – 123 (^{123}I-MIBG), sustancia análoga de la norepinefrina, se usa en la evaluación de la inervación miocárdica. Aunque el ^{123}I-MIBG no se une de forma directa al amiloide, provee información indirecta sobre la infiltración del sistema nervioso simpático cardíaco. Las imágenes de la captación cardíaca de ^{123}I-MIBG pueden detectar cambios en la inervación mucho antes que otras modalidades diagnósticas y tiene un amplio valor en el pronóstico del paciente y en la mortalidad a corto plazo.

Radiotrazadores de PET

Comparativamente con la técnica de SPECT, el PET/CT tiene mejor resolución espacial, y permite realizar una cuantificación mucho más absoluta de la carga de depósito de amiloide, aunque su uso en AC aún es limitado. Los trazadores de PET se pueden clasificar en dos categorías: agentes específicos del amiloide o agentes para el sistema óseo.

Los Radiotrazadores para uso en PET/CT de unión al amiloide son sustancias similares a la Tioflavina-T y son el ^{11}C-PiB; el ^{18}F-Florbetapir, el ^{18}F-Florbetaben y el ^{18}F-Flumetamol, que están aprobados por la FDA en imágenes de la enfermedad de Alzheimer y que han sido usados para imágenes de AC, pero no cuentan con aprobación de la FDA para el diagnóstico de AC y tampoco permiten hacer el diagnóstico diferencial con precisión de AC entre los tipos ATTR y AL. Permiten valorar la captación extracardíaca del amiloide.

Radiofármacos de PET para hueso

Las imágenes de PET con 18F-Fluoruro de Sodio (^{18}F-NAF) son prometedoras para el diagnóstico de AC, dada su mejor resolución espacial y permitiendo diagnosticar el compromiso cardíaco en etapas tempranas de la enfermedad y permitiendo una cuantificación más precisa, con la ventaja sobre otros trazadores de PET de poder diferenciar adecuadamente entre ATTR y AL.

Cuantificación

Para la interpretación de una gamagrafía ósea ante la sospecha de AC, se realizan análisis visuales y semicuantitativos. Para el análisis visual, se recomienda la comparación visual de la captación miocárdica con respecto al tejido óseo, llamado índice de Perugini, en el cual un resultado de 0 refleja la ausencia de captación miocárdica, el grado 1 es la captación miocárdica menor que la captación en costillas; el grado 2 es la captación miocárdica similar a la captación costal y el grado 3 es la captación miocárdica mayor que la captación costal. Se considera positivo para ATTR un índice mayor o igual a 2.

Para los índices semicuantitativos se han usado varias técnicas, como la retención cardíaca; la captación cardíaca correlacionada con la captación en todo el cuerpo; la relación de captación corazón versus cráneo o la relación de captación corazón versus captación en el tórax contralateral, siendo este último considerado mejor que el análisis visual.

Esta técnica semicuantitativa de las imágenes planares con radiofármacos para gamagrafía ósea (^{99}mTc-PYP; ^{99}mTc-DPD o ^{99}mTc-HMDP) se realiza mediante el índice de captación del miocardio versus el pulmón contralateral, tanto en las imágenes tempranas (de 1 hora) como en las tardías (3 horas). Valores de cuantificación mayores de 1.5 en las imágenes de 1 hora de inyección del radiotrazador y mayores de 1.3 en las imágenes tardías, permiten diferenciar con gran precisión la ATTR de la AL con una sensibilidad del 97% y una especificidad del 100%

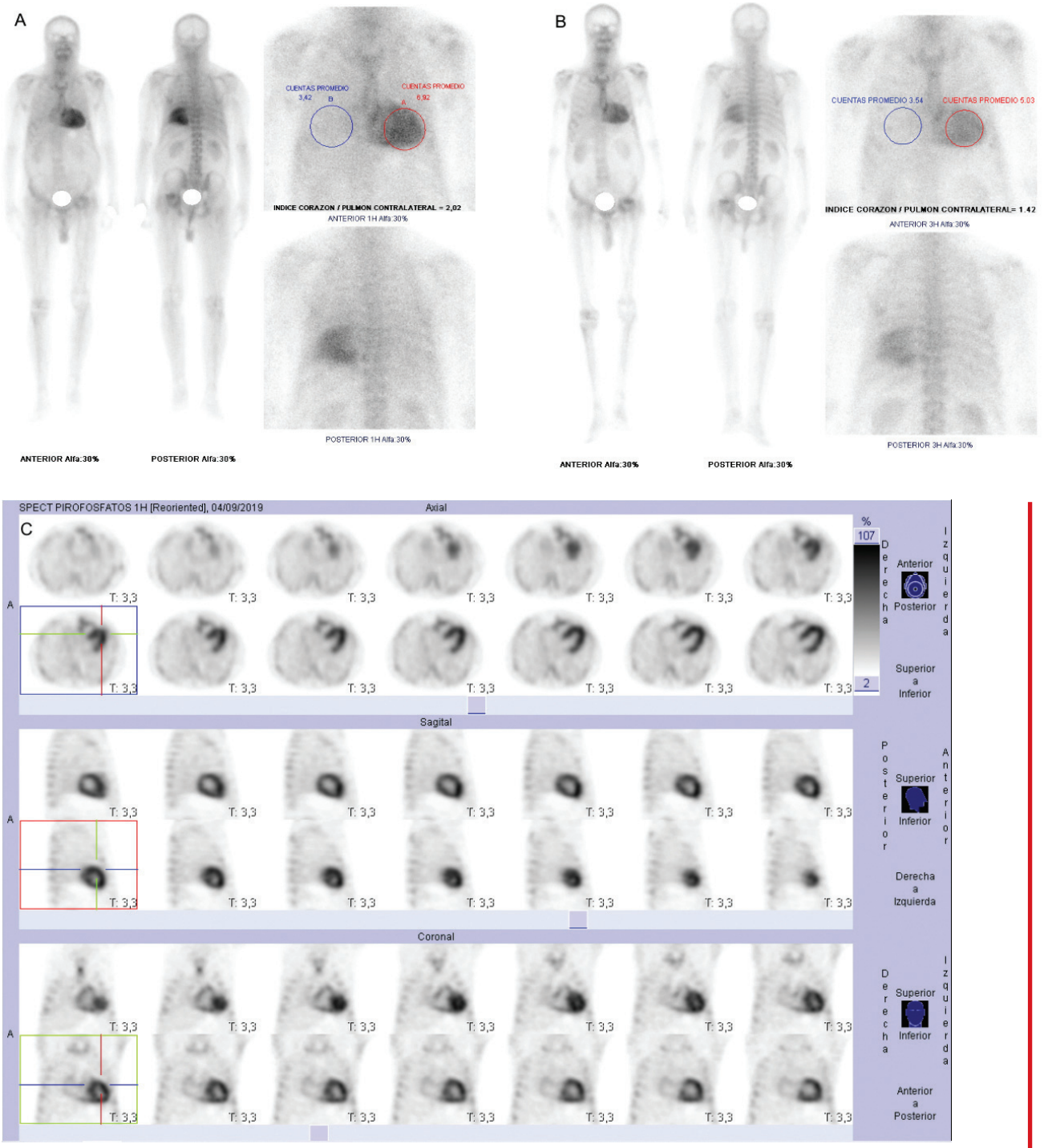

Figura 1.
Paciente de 55 años, con falla cardíaca con fracción de eyección preservada. Con sospecha de Amiloidosis cardíaca.

Gamagrafía ósea con 99mTc – Pirofosfato, 20 mCi de Tecnecio-99m. Imágenes de cuerpo entero, tórax anterior y posterior 1 hora después de la administración del radiofármaco (A) y 3 horas después (B). SPECT de tórax (C).

Índice de PERUGINI de 3 en las imágenes de 1 y 3 horas (captación cardíaca mayor que la captación costal). Índices de cuantificación corazón/pulmón contralateral positivos (mayor de 1.5 en la imagen de 1 hora y mayor de 1.3 en la imagen de 3 horas).

Conclusión: estudio compatible con Amiloidosis Cardíaca, de tipo ATTR.

Indicaciones para las imágenes de Medicina Nuclear con radiofármacos para el sistema óseo:

- Pacientes con falla cardíaca y aumento inexplicado del espesor de la pared del ventrículo izquierdo.

- Afroamericanos mayores de 60 años con falla cardíaca sin explicación o con espesor de la pared del ventrículo izquierdo mayor de 12 mm.

- Pacientes mayores de 60 años con falla cardíaca sin causa aparente y con fracción de eyección preservada.

- Ancianos, especialmente de sexo masculino con neuropatía sin causa aparente, con túnel del canal del carpo bilateral o fibrilación auricular sin los factores de riesgo asociados a ésta y signos o síntomas de falla cardíaca.

- Evaluación del compromiso cardíaco en pacientes con amiloidosis hereditaria sospechada o conocida.

- Diagnóstico de ATTR en pacientes con resultados compatibles con AC en una ecocardiografía o resonancia magnética cardíaca.

- Pacientes con sospecha de ATTR y contraindicaciones para la realización de una resonancia magnética cardíaca (insuficiencia renal o la presencia de un dispositivo metálico implantable).

- Valoración del riesgo de eventos cardíacos en pacientes con AC conocida.

- Valoración de la progresión de la enfermedad y valoración de la respuesta al tratamiento.

Tratamiento de la Amiloidosis cardíaca

Los tratamientos disponibles están dirigidos a reducir la producción o a estabilizar a la proteína precursora de los depósitos de amiloide y por lo tanto detener o disminuir la acumulación de amiloide. En la AL el tratamiento se dirige contra las células plasmáticas productoras de cadenas livianas. Recientemente medicamentos que silencian el gene de oligonucleótidos que inhiben la síntesis hepática del precursor de la proteína transtiretina han demostrado eficacia en la amiloidosis ATTR, con detención de la progresión de polineuropatía periférica y de la progresión de las manifestaciones cardíacas, incluso con reversión del compromiso cardíaco.

Conclusiones

El diagnóstico oportuno de la AC, en especial la del subtipo ATTR es más importante ahora que en el pasado. Los radiotrazadores para el sistema óseo útiles para imágenes cardíacas de amiloidosis han demostrado la habilidad de la medicina nuclear para el diagnóstico específico, temprano y no invasivo de la AC de tipo ATTR, evitando el uso de biopsia endomiocárdica.

La gamagrafía ósea para AC permite el tamizaje de poblaciones específicas con alto riesgo de AC de tipo ATTR. Los pacientes con falla cardíaca pueden ser diagnosticados por primera vez y de forma oportuna con AC de tipo ATTR y ser estratificados mediante el uso de esta técnica semicuantitativa, lo cual permite el uso temprano de nuevas terapias dirigidas y específicas que modificarán el curso de la enfermedad, mejorando el pronóstico, disminuyendo la cantidad de hospitalizaciones y mejorando y la sobrevida de los pacientes.

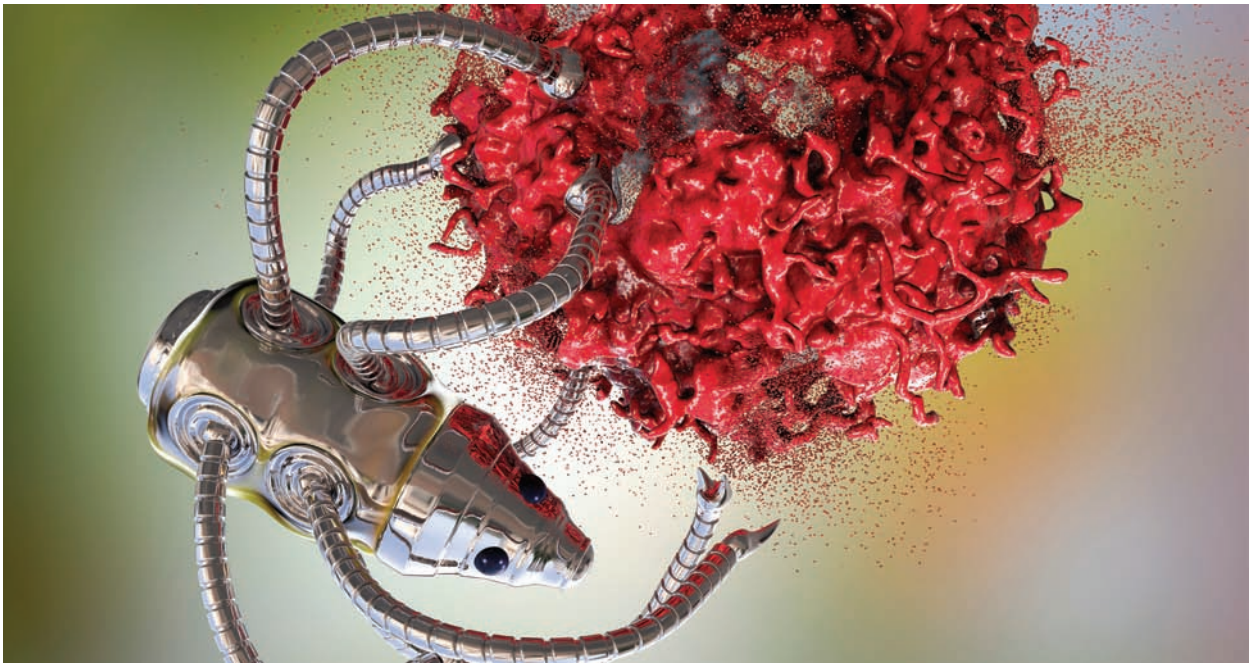

TECHNEGAS™

IMAGERIE PULMONAIRE FONCTIONNELLE

AVANTAGES
V/Q SPECT TECHNEGAS™

Précision de diagnostic prouvée
avec une sensibilité et une spécificité élevées [1]

Minimalement invasif
aide au confort et à la collaboration des patients [2]

Détection sous-segmentaire
de l'embolie pulmonaire (EP) [3]

Faible radiation
26 à 36 fois moins de dose absorbée au sein chez les femmes [4]

Technegas™ a des critères d'exclusion minimaux et peut être administré à la plupart des patients[4-6], y compris:
Insuffisance rénale | Allergie aux agents de contraste | Diabète
Maladie pulmonaire obstructive chronique (MPOC) | Gravement malade
Femme enceinte

V/Q SPECT TECHNEGAS™ ET LES RECOMMANDATIONS EN MÉDECINE NUCLÉAIRE

Les recommandations de l'EANM[7] conseillent fortement la tomographie par émission de photons pour les études pulmonaires de ventilation-perfusion (V/Q SPECT) car elle permet le diagnostic de l'EP avec précision, même en présence de MPOC et de pneumonie.

Les recommandations du CANM[8] considèrent Technegas™ comme l'agent de choix chez les patients souffrant de MPOC puisqu'il y a moins de dépôts dans les voies aériennes centrales, une meilleure pénétration périphérique et il ne s'élimine pas aussi rapidement que les aérosols traditionnels. Seulement quelques respirations sont suffisantes pour atteindre une quantité adéquate d'activité dans les poumons, ce qui réduit le temps de la procédure et l'exposition du personnel.

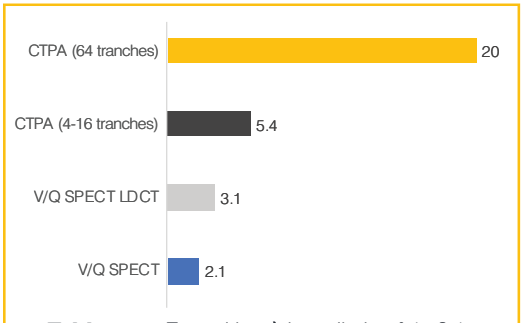

Tableau 1: Exposition à la radiation [8] (mSv) (adapté des recommandations du CANM, 2018)

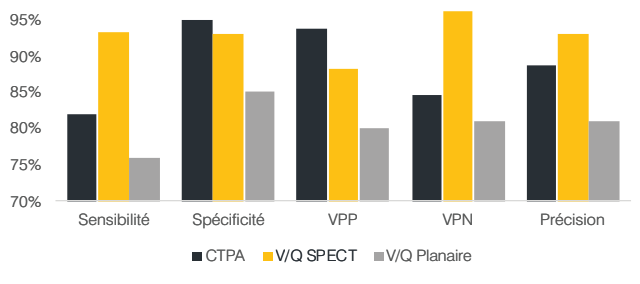

Tableau 2: Performances diagnostiques des différentes modalités à détecter l'EP (adapté de Hess et al, 2016)

Toutes les EP doivent avoir un contrôle final 3 mois après le diagnostic afin d'évaluer la reperfusion finale et pour bénéficier de la disponibilité d'un examen de base en cas de symptômes récurrents. Une faible exposition à la radiation permet des études répétées (tableau 1).

Avec l'adoption de l'imagerie SPECT, les résultats V/Q SPECT sont considérés comme supérieurs à l'imagerie planaire et à la tomodensitométrie (CTPA) lorsque l'on compare la sensibilité, la valeur prédictive négative et la précision de ces examens (tableau 2).[1]

Par conséquent, dans les situations d'EP aiguës, d'EP chroniques, de grossesse, de pédiatrie et de patients MPOC, l'imagerie V/Q SPECT peut être considérée comme une investigation de première ligne en raison de sa sensibilité et de sa spécificité élevées, de sa faible radiation et de l'absence d'effets indésirables.[8]

Références

1. Hess S, et al. Semin Thromb Hemost 2016; 42: 833–845
2. Sánchez-Crespo A, et al. Nucl Med Commun 2008; 29(2): 173-177
3. Grüning T, et al. Clin Imaging 2014; 38(6): 831-835
4. Isidoro J, et al. Phys Med 2017; 41: 93-96
5. Miles S, et al. Chest 2009; 136: 1546-1553
6. Nasr A, et al. EC Pulmon and Respir Medicine 2017; 4(3): 85-91
7. Bajc M, et al. Eur J Nucl Med Mol Imaging 46, 2429–2451
8. Leblanc M , et al. CANM Guidelines 2018; publié Nov 2018

AFIN D'EN APPRENDRE DAVANTAGE SUR LA PROCÉDURE V/Q SPECT AVEC TECHNEGAS™, VISITEZ : https://bit.ly/2PZDDii

Technegas™ n'est pas encore disponible à la vente aux États-Unis.
Dernière révision (A4): v.2.1 (14/avr/2021)
Pour plus d'informations, veuillez visiter **www.cyclomedica.ca** ou envoyer un courriel à **technegas.sales@cyclomedica.ca**

cyclomedica

Christian Scheiber
MD, PhD
Chef du service de Médecine Nucléaire –
Hospices Civils de Lyon - France

INDICATIONS DE LA SCINTIGRAPHIE DE LA VOIE DOPAMINERGIQUE PRÉ-SYNAPTIQUE PAR LE DATSCAN™ DANS LE BILAN DES SYNDROMES PARKINSONIENS

Comprendre un test comme le DaTSCAN™ demande une connaissance préalable de la voie dopaminergique qu'il explore. On appelle système dopaminergique ou voie dopaminergique l'ensemble des neurones communiquant entre eux par une molécule (neurotransmetteur) appelée dopamine. Les structures anatomiques concernées sont une région du mésencéphale (la partie compacte ('*pars compacta*') de la substance noire) et les terminaisons de ces neurones au niveau du striatum (régions de haute densité neuronale dont la structure anatomique fine révèle une organisation en couches leur donnant un aspect strié). Pour cette raison on appelle cette voie neurologique la voie nigro-striée. (Figure 1). Le striatum est composé de plusieurs amas cellulaires. Anatomiquement on distingue : le putamen localisé dans la région postérieure et le noyau caudé qui est dans la région antéro-supérieure. Ces noyaux ont des fonctions différentes complexes mais qui, pour faire très simple, sont motrices (contrôle musculaire pour le putamen) et cognitives (connexion avec les régions frontales exécutives).

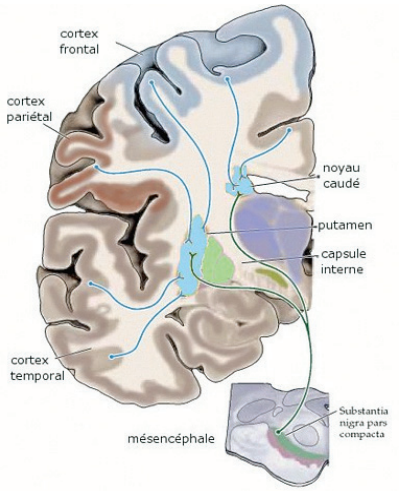

Figure 1 : schéma d'une coupe coronale du cerveau illustrant l'origine de la voie nigro-striée dans la substance noire mésencéphalique et ses terminaisons synaptiques dans le putamen et le noyau caudé (composants du striatum).

Le fonctionnement de ces régions est très complexe et n'est pas abordé ici. Cette voie est indispensable au contrôle des mouvements du corps, en particulier les mouvements automatiques (par exemple, les expressions du visage). Une atteinte fonctionnelle ou organique de cette voie se traduit par un ralentissement et/ou un contrôle insuffisant des mouvements (tremblement, lenteur, rigidité). La partie gauche du cerveau contrôle le côté droit du corps et l'atteinte de la voie dopaminergique gauche donnera un syndrome Parkinsonien droit (controlatéral) et réciproquement pour l'atteinte de la voie droite.

La maladie de Parkinson est la plus connue des pathologies de la voie dopaminergique, elle se déclare le plus souvent chez une personne de plus de 60 ans et se caractérise par des signes moteurs (le syndrome extrapyramidal), mais aussi par d'autres signes non-moteurs parfois plus difficiles à reconnaître. On sait aujourd'hui que les pathologies extrapyramidales sont très hétérogènes dans leur présentation clinique et leur pronostic. Différentes pathologies peuvent être responsables d'un syndrome Parkinsonien. Ceci ne traduit pas forcément une lésion mais, plus fréquemment, un dysfonctionnement du système dopaminergique. Parfois il s'agit d'une maladie génétique.

Le plus souvent il s'agit d'une maladie neurodégénérative par réduction trop rapide pour l'âge du nombre de neurones de la voie dopaminergique. Le cerveau a une réserve fonctionnelle qui atteint ses limites quand environ 50-60 % de la population neuronale a disparu. Dans la maladie de Parkinson il existe une dégénérescence de la substance noire (Figure 2). Il s'agit d'une synucléopathie (accumulation anormale d'agrégats de protéine synucléine). Les synucléopathies les plus fréquentes sont la maladie de Parkinson, la maladie à corps de Lewy (MCL) et les atrophies multisystématisées (AMS).

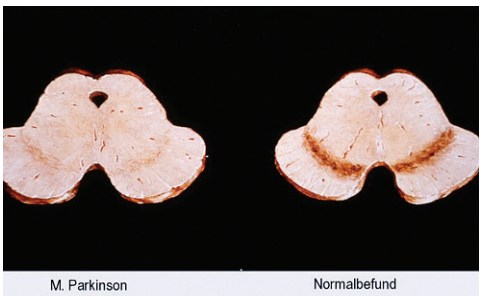

Figure 2 : coupe histologique du mésencéphale après coloration argentique des neurones dopaminergiques dans la pars compacta de la substance noire chez un patient atteint de la maladie de Parkinson (à gauche) comparée à celle d'un sujet sain. On note la décoloration traduisant la dégénérescence des neurones.

Plus rarement c'est une destruction progressive des neurones striataux (maladie de Huntington). Parfois la cause peut être un accident vasculaire qui détruit les structures ou interrompt les voies de transmissions dopaminergiques. Les syndromes Parkinsoniens atypiques regroupent un ensemble de maladies qui ont en commun une atteinte de la voie dopaminergique mais intéressent également d'autres structures anatomiques proches ou distantes. Parmi elles on retrouve la maladie à corps de Lewy, qui est également une synucléopathie proche de la maladie de Parkinson et caractérisée par une accumulation de lésions caractéristiques : les corps de Lewy, se retrouvent disséminés dans l'encéphale. D'autres synucléopathies sont plus complexes comme les atrophies multisystématisées. Mais on retrouve aussi un syndrome Parkinsonien dans la paralysie supra-nucléaire progressive (PSP) et la démence cortico-basale (DCB) qui sont des tauopathies (accumulation de protéine tau). Ces pathologies ont toutes en commun un diagnostic clinique difficile au début de leur évolution.

Ces maladies neurodégénératives n'ont pas de traitement curatif ni même protecteur (des études sont cependant en cours avec cet espoir). Cependant il existe dans plusieurs situations des traitements spécifiques, dopaminergiques et/ou agonistes dopaminergiques qui permettent une amélioration clinique au moins temporaire. C'est fréquemment le cas au début de l'évolution d'une maladie de Parkinson idiopathique qui représente 80% des syndromes Parkinsoniens. La perte neuronale se poursuit, associée à une aggravation clinique, ceci oblige une augmentation progressive du traitement avec les risques inhérents à leurs effets secondaires.

Le médecin reconnaît facilement un syndrome extrapyramidal complet mais il existe des formes frustes surtout au début de l'évolution. Un test thérapeutique permet de trancher en améliorant les signes cliniques mais seulement dans 50 % des cas.

Les neurones dopaminergiques diminuent au cours de la vie de façon significative (près de 50 % en moins sur une vie de 70 ans). Il faut en tenir compte pour l'interprétation.

L'examen DaTSCAN™ : l'exploration par neuro-imagerie de la voie dopaminergique permet de faire le diagnostic positif de son atteinte de plusieurs façons mais la scintigraphie au DaTSCAN™ est la plus commune parce que la plus disponible et la plus fiable. Le DaTSCAN™ ou ioflupane (123I-FP-CIT) est un analogue de la cocaïne. Comme cette drogue l'analogue vient se fixer spécifiquement pendant quelques heures sur une petite fraction de la population d'une protéine appelée transporteur de la dopamine localisée dans la membrane des terminaisons pré-synaptiques striatales. Ce transporteur de la dopamine (en anglais Dopamine Transporteur ou DaT, DaTSCAN™) a un rôle dans la recapture de la dopamine qui a servi dans la neurotransmission.

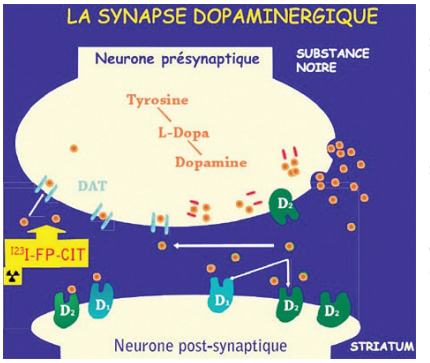

Figure 3 : schéma de la synapse dopaminergique avec entre autres un des transporteurs de la dopamine (DAT) sur le versant pré-synaptique sur lequel vient se fixer le DaTSCAN@ (123I-FP-CIT). La fixation est stable 3H après l'injection et pour environ 1H.

La molécule est marquée par un isotope radioactif, ici l'iode 123 (émetteur gamma de 159 keV). Ces molécules sont des médicaments radiopharmaceutiques. Comme tout radiopharmaceutique le DaTSCAN™ est administré à une dose « traceur » c'est-à-dire en très faible quantité : il permet de localiser et dénombrer les sites « fonctionnels » mais ne peut pas avoir d'action pharmacologique.

L'exposition est de l'ordre de 4 mSv pour 185 MBq de DaTSCAN™ injectés, c'est-à-dire de l'ordre de grandeur de l'exposition naturelle d'une année aux rayonnements ionisants. Pour respecter un principe de précaution la glande thyroïde (avide d'iode) aura été temporairement bloquée avant l'injection intraveineuse.

L'examen dure 30 minutes sur la table d'une gamma-caméra du service de Médecine Nucléaire et est réalisé trois heures après l'injection intraveineuse quand la fixation du DaTSCAN atteint un plateau. Ces caméras sont souvent couplées avec un scanner X (tomodensitomètre X) qui est utilisé pour améliorer la précision des mesures (correction de l'atténuation des rayonnements) mais aussi pour l'analyse de la morphologie cérébrale. Ces informations peuvent être utiles à l'interprétation des images devant un syndrome Parkinsonien atypique, une situation fréquente en médecine nucléaire.

Après traitement des données, la scintigraphie cérébrale représente la distribution de la radioactivité émise par le traceur. Pour tenir compte d'une fixation non-spécifique dans le cerveau (ailleurs que sur ces terminaisons neuronales dopaminergiques) on calcule des index de fixation, ou potentiel de liaison, qui expriment la concentration locale du traceur et donc du nombre de neurones fonctionnels. Ce rapport vaut pour le putamen P (activité P- activité de la région occipitale) / activité P. L'estimation de ces rapports est un challenge de mesures et des corrections doivent être appliquées (atténuation et diffusion du rayonnement, résolution spatiale de l'appareil etc..) qui sortent de l'objectif de cet article.

Contre-indications : seule la grossesse est une contre-indication, mais l'examen n'est parfois pas réalisable chez certains patients sans prémédication (par exemple chez les patients claustrophobes). Il n'y a pas de réaction allergique à l'iode avérée ce qui s'explique par la faible teneur en iode du médicament (traceur) et au

mécanisme de l'allergie à l'iode. On demande toutefois d'informer le patient et des précautions particulières peuvent être prises au besoin.

Interactions médicamenteuses et précautions à prendre avant l'examen : Le DaTSCAN™ entrera en compétition pour sa fixation sur le transporteur de la dopamine avec toute molécule (traitement, drogue) se fixant de la même façon : les dérivés de la cocaïne au premier chef mais aussi les amphétamines (par exemple la Ritaline™) et certains antidépresseurs comme la Sertraline (Zoloft™) qui doivent être arrêtés une semaine avant l'examen. Il existe d'autres médicaments qui ont des interactions plus faibles mais mesurables. La liste est connue des neurologues, gériatres, psychiatres, principaux prescripteurs de cet examen. Les éventuels traitements qui seraient conservés le jour de l'examen doivent être connus du médecin nucléaire qui en tiendra compte lors de son analyse.

IMAGERIE NORMALE - INTERPRÉTATION DES IMAGES PATHOLOGIQUES

Le DaTSCANTM se fixe préférentiellement sur le transporteur de la dopamine qui est très dense dans les terminaisons pré-synaptiques striatales des neurones dont le corps cellulaire est dans la substance noire. Sa fixation dans ces régions est proportionnelle au nombre de synapses fonctionnelles.

L'interprétation se fait par analyse visuelle des images du striatum qui sont codifiées en 4 catégories illustrées dessous, de gauche à droite : normale, anormale type 1, 2 et 3 (PCNS advisory document, 2009).

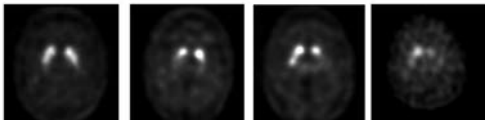

Figure 4 : images normale et pathologiques de la fixation du DaTSCANTM sur le striatum. Extrait du PCNS advisory document, 2009.

L'image normale en virgule (ou croissant) est symétrique et superposable à l'anatomie du striatum.

La physiopathologie de la maladie de Parkinson se traduit par une dégénérescence des terminaisons putaminales plus précoce que celles des terminaisons caudées et qui est rarement symétrique. L'évolution de la fixation des images reflète la dégénérescence mais n'est pas toujours superposable aux signes cliniques compte tenu de mécanismes compensateurs à différents niveaux. Le médecin nucléaire précise la voie la plus atteinte et la notion d'un gradient putamen-caudé quand il existe et témoignant d'une atteinte plus sévère du noyau putamen que du noyau caudé. En pratique les signes cliniques n'apparaissant que pour une disparition de plus de 50 % (pour certains 60 voire 70 %) des terminaisons dopaminergiques, les images sont pathologiques (type 2, 3 ou 4) lors de la réalisation de l'examen s'il existe une atteinte de la voie dopaminergique. Une atteinte au début se manifestera par une réduction de la fixation de la partie postérieure du noyau putamen gauche si les signes cliniques sont à droite (controlatéral aux signes cliniques). Une analyse fine chez la personne de plus de 70 ans demande de l'expérience car la fixation physiologique du traceur diminue avec l'âge reflétant la perte neuronale physiologique d'environ 0,6 % par an. Un gradient antéro-postérieur pathologique doit être distingué de l'image normale pour l'âge.

Depuis 2009, les caractéristiques des gamma-caméras ont été améliorées. Cela concerne, entre autres, une meilleure résolution spatiale permettant de discriminer le noyau caudé du noyau putamen, et une meilleure résolution en énergie permettant des études en double isotope (deux traceurs différents marqués par des isotopes radioactifs différents) de meilleure qualité. Ces gamma-caméras permettent d'obtenir des images diagnostiques pour des activités injectées plus faibles de l'ordre de 111 MBq (limite inférieure des recommandations internationales) réduisant ainsi l'exposition du patient en proportion et à durée d'acquisition constante (30 minutes).

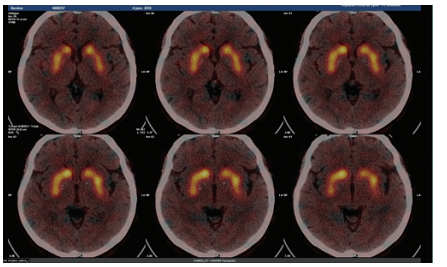

Figure 5 : coupes axiales couvrant le volume du striatum réalisées trois heures après injection de 111 MBq de ^{123}I FP-CIT (DaTSCAN™) et 30 minutes d'acquisition sur une caméra 670 CZT General Electric. Cette image normale permet de visualiser la partie antérieure (tête) du noyau caudé et le noyau putamen plus en arrière.

Il est recommandé de compléter l'analyse visuelle par une analyse semi-quantitative qui exprime les index de potentiel de liaison du patient par rapport à une base de données normale pour l'âge. Il existe plusieurs bases de données normales disponibles. Certaines sont implémentées dans des logiciels d'analyse dédiés comme le DaTQUANT® de la société General Electric (Figure 6).

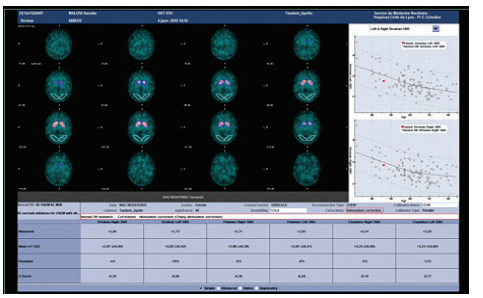

Figure 6 : le logiciel DaTQUANT® permet de comparer les résultats d'un patient avec ceux d'une base de données normales pour l'âge (ici celle du projet PPMI, USA). Sur les deux graphiques, on note un point rouge identifiant l'index du striatum du patient sur un graphe contenant les valeurs normales en fonction de l'âge (valeur moyenne et ± 95 % d'intervalle de confiance). Le tableau rapporte les valeurs des index et l'écart à la moyenne pour l'âge du patient.

La dispersion des valeurs normales autour de la moyenne pour un âge donné reflète en partie des

incertitudes instrumentales mais principalement une variabilité physiologique. Le DaTSCANTM permet d'estimer une diminution régionale (une partie du striatum) de l'ordre de 20 %, bien inférieure à celle qui va donner des signes cliniques. L'indication de l'examen se fait sur la présence de ces signes (le syndrome extrapyramidal) et en conséquence les index sont toujours très pathologiques le jour de l'examen si la maladie est présente. De fait, il est rare de constater une atteinte dopaminergique toute débutante, limitée à la partie postérieure d'un des putamen. L'analyse visuelle reste nécessaire. Il sera parfois difficile d'éliminer une atteinte débutante discrète chez la personne âgée si elle est symétrique.

Les images « normales » pour l'âge se retrouvent jusqu'à un âge avancé (Figure 7). Physiologiquement on note une diminution modérée de la fixation de la partie postérieure du putamen qui est en général symétrique.

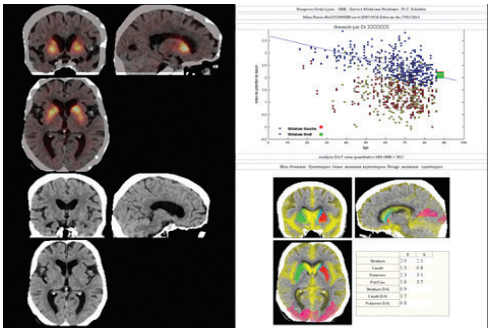

Figure 7 : exemple d'un DaTSCAN™ normal chez un patient de 90 ans dont les index ont été calculés avec un autre logiciel. Le graphe donne en bleu les valeurs normales en fonction de l'âge et en rouge les valeurs pathologiques usuellement rencontrées dans un groupe apparié en âge.

Certaines pathologies se traduisent par une perte plus homogène de la densité de terminaisons synaptiques et l'analyse visuelle n'est plus performante. Les effets éventuels d'une interaction médicamenteuse (compétitive) sont mesurés par l'analyse semi-quantitative comme chez cette patiente qui n'avait pas suivi la demande d'arrêt des amphétamines (Figure 8). Il n'est pas possible de différencier les deux examens par l'analyse visuelle. Ce sera le cas pour toute diminution globale/homogène de la fixation comme on peut parfois la rencontrer dans des indications pour syndrome Parkinsonien atypique.

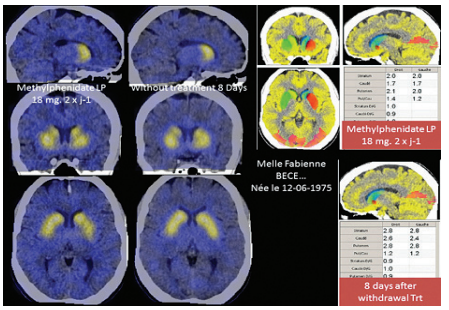

Figure 8 : deux examens DaTSCANTM d'une jeune patiente sous traitement par amphétamines et qui n'avait pas arrêté son traitement. La fixation est homogène mais diminuée. A droite l'image et les index sont redevenus normaux 8 jours après sevrage.

LES INDICATIONS DU DATSCAN™ EN ROUTINE CLINIQUE

Le diagnostic de **maladie de Parkinson** est clinique devant la mise en évidence du syndrome extrapyramidal mais, au début de la maladie, la symptomatologie peut être fruste et/ou atypique. Ce patient de 45 ans présentait un tremblement du membre inférieur droit depuis quelques mois et le DaTSCANTM a été demandé en raison de son jeune âge. Il montre une atteinte surtout du putamen gauche dont on ne distingue plus que le 1/3 antérieur et de la partie postérieure du putamen droit qui était asymptomatique : ces images sont assez caractéristiques de maladie de Parkinson débutante (Figure 9). Les images sont pratiquement toujours anormales des deux côtés mais asymétriques, en controlatéral des signes cliniques. L'atteinte putaminale (la réduction de la fixation) est toujours plus marquée avec un gradient antéro-postérieur. Ces images reflètent l'évolution naturelle de la dégénérescence de la substance noire. L'index striatal du côté le moins atteint peut rester dans la moyenne pour l'âge au début de l'évolution chez un patient sans symptomatologie extrapyramidale franche.

En imagerie nous utilisons des échelles de couleur pour faire apparaitre des différences significatives dans les images. Pour le DaTSCAN™ elle discrimine les régions de moins de 50 % de la normale (seuil symptomatologie clinique). Les images DaTSCAN™ ne reflètent que la fixation du traceur sur le transporteur de la dopamine et les mécanismes compensateurs peuvent expliquer une partie des discordances entre les signes scintigraphiques et la clinique souvent en retrait par rapport aux valeurs mesurées. En particulier au début de la maladie.

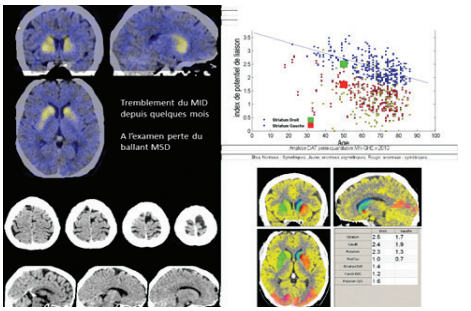

Figure 9 : image caractéristique d'un patient, quelques mois après l'apparition des signes cliniques (ici tremblement du membre inférieur droit). – On note l'atteinte putaminale gauche et déjà de la partie postérieure du putamen droit. L'index gauche (carré rouge) est en-dessous de la valeur normale pour l'âge. L'index striatal droit reste dans les limites de la normale bien que la partie postérieure du putamen soit atteinte. Nécessité d'une interprétation visuelle et numérique.

La première indication du DaTSCAN™ a été le diagnostic différentiel d'un tremblement essentiel atypique. Le tremblement essentiel n'a pas d'étiologie connue, il est fréquent dans la population. Quand il est typique, ce qui est le plus souvent le cas, c'est un tremblement fin d'attitude. Dans certaines situations il peut être/devenir atypique faisant suspecter une atteinte de la voie dopaminergique. L'examen au DaTSCAN™ est strictement normal pour l'âge comme l'illustre le résultat de l'examen ci-dessous devant un

tremblement essentiel dont le diagnostic remonte à plus de 10 ans, mais qui se complète depuis quelques mois d'une composante de repos et l'apparition d'autres signes de la série extrapyramidale (hypomimie) (Figure 10).

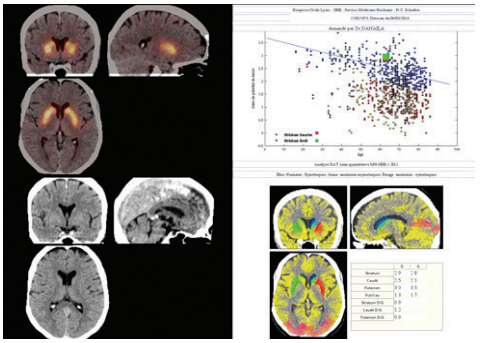

Figure 10 : image DaTSCAN™ normale chez un patient présentant une évolution récente de son tremblement qualifié d'essentiel, connu depuis 10 ans.

Plus rarement il s'agira d'un **diagnostic différentiel entre une dégénérescence dopaminergique vraie et un Parkinson iatrogène** : le diagnostic d'un syndrome extrapyramidal (syndrome Parkinsonien) chez un patient sous neuroleptiques (y compris dernière génération). Les neuroleptiques agissent sur la voie dopaminergique en bloquant les récepteurs post-synaptiques. Le syndrome extrapyramidal clinique est donc identique à celui observé par dégénérescence pré-synaptique. Le syndrome post-neuroleptique peut persister malgré l'arrêt du traitement et peut aussi survenir rapidement ou après des dizaines d'années de prise médicamenteuse chez des patients psychotiques. Le patient peut en parallèle présenter un début de dégénérescence dopaminergique qui se révèle cliniquement du fait d'un blocage post-synaptique additionnel thérapeutique.

Le DaTSCAN™ sera normal ou pathologique en fonction de la contribution éventuelle d'une dégénérescence et permettra de l'estimer si une analyse semi-quantitative est effectuée. Les demandes cliniques sont très variées et souvent complexes comme chez ce patient âgé de 85 ans qui présentait un syndrome extrapyramidal avec des troubles cognitifs, l'ensemble aggravé par les neuroleptiques avec des antécédents d'accident vasculaire ischémique frontal droit. Le DaTSCAN™ était strictement normal pour l'âge permettant d'exclure une atteinte de la voie dopaminergique pré-synaptique (Figure 11).

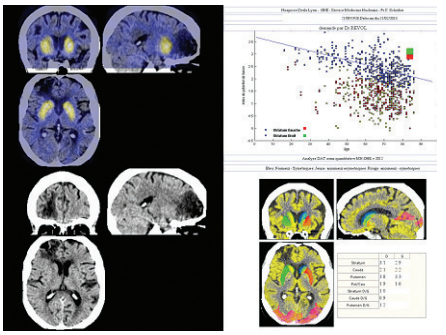

Figure 11 : en haut à gauche image DaTSCAN™ normale chez un patient présentant un syndrome frontal post-ischémique avec syndrome extrapyramidal récemment aggravé par la prise de neuroleptiques. A droite la courbe confirme des index normaux pour l'âge.

Plus rarement se posera le diagnostic d'un pseudo-syndrome-parkinsonien chez une patiente psychiatrique avec un syndrome extrapyramidal dont un tremblement d'origine psychogène. L'image DaTSCAN™ de contrôle et ses valeurs semi-quantitatives se sont avérées strictement normales. Il est utile de souligner l'importance d'un recalage précis des images (méthode automatique ou manuelle) car un écart peut conduire à une erreur d'interprétation devant une asymétrie qui serait positionnelle. C'est ce qui était arrivé chez cette patiente où un premier examen, de qualité insuffisante, avait conclu à une atteinte dopaminergique débutante (Figure 12).

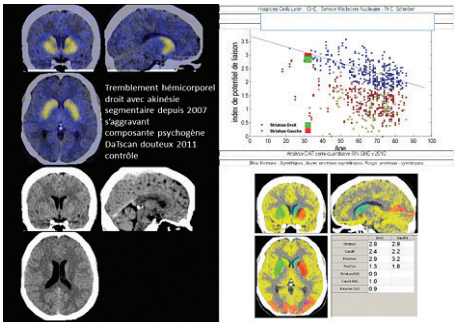

Figure 12 : DaTSCAN™ strictement normal chez cette jeune femme sans antécédent psychiatrique mimant parfaitement un syndrome Parkinsonien.

SYNDROME PARKINSONIEN ATYPIQUE

L'atteinte neurologique concerne d'autres systèmes en plus du système dopaminergique. La scintigraphie DaTSCAN™ est en général anormale mais le type d'anomalie n'est pas caractéristique d'une pathologie particulière. Ces maladies sont les suivantes : atrophie multisystématisée (AMS), Paralysie supranucléaire progressive (PSP), dégénérescence cortico-basale (DCB) et la maladie à corps de Lewy diffus (MCL). A un stade évolué, les troubles cognitifs sont tels que le patient devient dépendant et on parle de démence.

Ces pathologies neurologiques sont complexes et leur phénotype clinique très divers. Souvent seule l'évolution clinique, parfois après plusieurs années, permettra le diagnostic. Les signes radiologiques (IRM), d'atrophie le plus souvent, sont souvent discrets à la première consultation. Un des avantages de la médecine nucléaire est de montrer des signes de dysfonctionnement précoce, ici de la voie dopaminergique, dans un contexte d'imagerie cérébrale (encore) normale.

L'atteinte dopaminergique pré-synaptique explorée par le DaTSCAN™ ne donne qu'exceptionnellement une information pertinente sur la pathologie en cause, mais la preuve de cette atteinte et son étendue est une aide précieuse pour le clinicien. Si la séméiologie de l'image DaTSCAN™ est rarement caractéristique, le médecin pourra s'appuyer également sur les signes morphologiques obtenus par le scanner X et sur les résultats de l'analyse semi-quantitative.

Maladie à corps de Lewy disséminés (MCL) : cette maladie neurodégénérative est en fréquence la seconde cause de démence derrière la maladie d'Alzheimer avec environ 5-15 % de l'ensemble.

La MCL est due à des lésions spécifiques, les corps de Lewy, avec des dépôts anormaux d'une protéine synucléine (comme la maladie de Parkinson). Les corps de Lewy se retrouvent dans tout le cerveau et pas seulement dans la substance noire (maladie de Parkinson). Elle peut se développer seule ou associée à une maladie d'Alzheimer (MA) ou une maladie de Parkinson. Le DaTSCAN™ est fortement abaissé chez près de 85% des patients (Figure 13) alors qu'il reste normal pour l'âge chez un patient atteint de maladie d'Alzheimer.

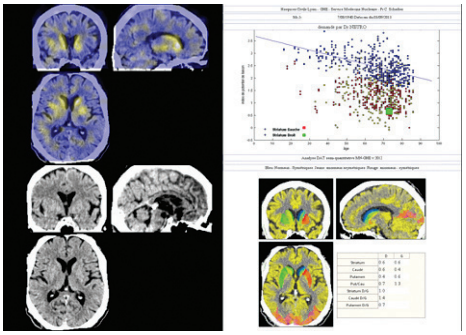

Figure 13 : DaTSCAN™ d'un patient atteint d'une maladie à corps de Lewy qui montre une fixation très faible du striatum (images, index) alors que le syndrome extrapyramidal était très discret. Dans cette maladie le DaTSCAN™ est en général symétrique et montre une très faible fixation.

Le diagnostic est parfois difficile en raison de la discrétion des signes extrapyramidaux et l'importance des troubles cognitifs. Le diagnostic est important à effectuer car la MCL évolue plus rapidement que la MA et surtout ces patients sont très sensibles aux neuroleptiques qui sont cependant formellement contre-indiqués. L'examen par le DaTSCAN™ est un des critères qui permet de définir la probabilité diagnostique de cette pathologie chez des patients présentant des troubles cognitifs et peu ou pas de symptômes extrapyramidaux.

Le DaTSCAN™ est indiqué quand la recherche d'argument en faveur d'une maladie à corps de Lewy est nécessaire, entre autres, pour le diagnostic différentiel avec la maladie d'Alzheimer. La gamma-caméra permet de réaliser des examens en double isotopes permettant d'explorer simultanément la perfusion cérébrale, par exemple par l'HMPAO ^{99m}Tc (gamma, 140 keV), et la voie dopaminergique par le DaTSCAN™ (Figure 14). Les hypoperfusions éventuelles sont corrélées avec les signes d'atrophie (scanner X) et interprétées conjointement avec le résultat du DaTSCAN™.

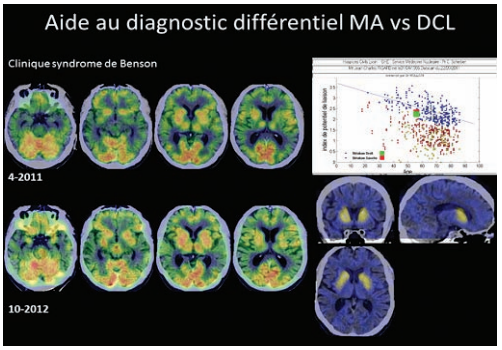

Figure 14 : un examen hybride de perfusion cérébrale à l'HMPAO et DaTSCAN™ chez un patient présentant des signes en faveur d'une maladie d'Alzheimer atypique (syndrome de Benson) mais dont le diagnostic différentiel avec une maladie à corps de Lewy était difficile. L'examen DaTSCAN™ était strictement normal permettant de réduire le risque de MCL et la scintigraphie cérébrale (réalisée en 2011 et 2012) montre la stabilité des hypoperfusions étendues telle qu'on les rencontre dans la maladie d'Alzheimer (par exemple).

L'Atrophie multisystématisée se rencontre sous la forme Parkinsonienne dominante (AMS-P, chez 80% des patients) d'expression clinique proche du Parkinson, mais d'évolution rapide (6-8 ans) avec d'importants signes d'atteinte autonome et une forme cérébelleuse (AMS-C, 20 % des patients). Dans l'AMS-C, en sus de l'atteinte dopaminergique (DaTSCAN™ pathologique), il existe, entre autres, une atteinte du cervelet avec des troubles de la coordination des mouvements (ataxie), des troubles du système nerveux autonome et des signes d'atteinte de la voie pyramidale (motricité volontaire). L'imagerie morphologique couplée (examen hybride avec un scanner X couplé) permet de donner une orientation diagnostique sur la reconnaissance d'une atrophie cérébelleuse (AMS-C) comme chez ce patient de 72 ans (Figure 15).

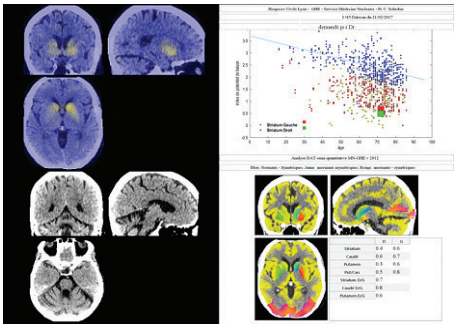

Figure 15 : DaTSCAN™ en faveur d'une atteinte dopaminergique pré-synaptique bilatérale sévère dans un contexte clinique évoquant une AMS-C. Le diagnostic est rendu plus probable encore sur l'image TDM d'atrophie cérébelleuse.

La Paralysie supranucléaire progressive (PSP) est une tauopathie comme la maladie d'Alzheimer qui se caractérise par des chutes précoces et une limitation progressive des mouvements des yeux (l'oculomotricité). Chez ces patients présentant un syndrome Parkinsonien atypique, l'atteinte dopaminergique est souvent globale et symétrique ce qui rend moins probable une maladie de Parkinson idiopathique classiquement asymétrique et intéressant plus le putamen (au stade du diagnostic).

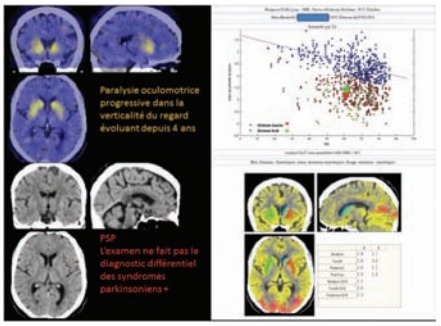

Figure 16 : DaTSCAN™ d'une patiente atteinte d'une paralysie de l'oculomotricité progressive faisant craindre une PSP. L'atteinte est bilatérale et asymétrique. Sur l'image DaTSCAN™ seul l'abaissement global de la fixation du striatum droit (index droit abaissé) permet d'évoquer une pathologie autre qu'une maladie de Parkinson. L'imagerie morphologique est encore subnormale à ce stade.

La Dégénérescence cortico-basale (DCB) associe une atteinte corticale (en général fronto-pariétale) et une atteinte striatale homolatérale. Les signes cliniques sont

classiquement moteurs sous forme d'un trouble d'aggravation progressive de la réalisation de certains mouvements (apraxie motrice) mais la présentation clinique est souvent dominée par les troubles cognitifs (atteinte frontale). DCB et PSP sont présentées comme des entités distinctes pour faciliter le diagnostic et la compréhension de ces pathologies complexes qui sont parfois regroupées sous la dénomination de complexe de maladie de Pick. L'examen au DaTSCAN™ est classiquement très asymétrique permettant de mesurer l'atteinte dopaminergique striatale et c'est l'imagerie morphologique couplée qui apporte une information complémentaire nécessaire en objectivant une atrophie corticale du même côté du cerveau. Celle-ci est souvent discrète et demande, comme pour le DaTSCAN™, un recalage, voire une mise en correspondance dans un espace anatomique standard, pour être étudiée. Quand les signes sont discrets, il est utile de pratiquer un examen en double isotope associant au DaTSCAN™ un traceur de la perfusion comme l'HMPAO-^{99m}Tc qui confirmera la réduction de la perfusion de la région anatomique suspecte d'atrophie. L'exemple ci-dessous est académique, les signes d'atrophie sont suffisamment marqués pour permettre d'évoquer le diagnostic sans l'aide d'une scintigraphie de perfusion (Figure 17).

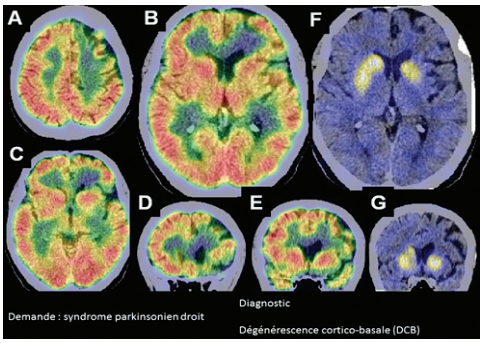

Figure 17 : A à E scintigraphie de perfusion cérébrale à l'HMPAO montrant la diminution de la perfusion corticale frontale gauche bien corrélée avec les signes d'atrophie. F et G DaTSCAN™ de ce patient qui présentait un syndrome Parkinsonien droit montrant la diminution de la fixation du putamen. Dégénérescence cortico-basale.

Les syndromes Parkinsoniens peuvent également être secondaires à une atteinte vasculaire et le DaTSCAN™ permettra d'objectiver l'étendue de l'atteinte dopaminergique pré-synaptique. Pour un compte-rendu plus complet, on s'appuiera sur l'imagerie morphologique couplée qui localise et précise l'étendue des séquelles ischémiques comme chez ce patient qui présente un syndrome Parkinsonien gauche séquellaire d'un accident vasculaire ischémique de la branche profonde de l'artère Sylvienne gauche et responsable d'une destruction partielle du striatum (Figure 18).

EN CONCLUSION

Le DaTSCAN™ est un examen de routine clinique performant, bien codifié et fiable pour une estimation de l'atteinte du système dopaminergique pré-synaptique sous réserve d'un sevrage de traitements compétitifs pour le transporteur de la dopamine.

Dans la majorité des situations cliniques, le clinicien peut résoudre le problème diagnostic par un examen neurologique et parfois aidé par une IRM cérébrale. La situation est plus difficile au début de l'expression clinique de la maladie y compris pour la maladie de Parkinson. Devant un syndrome Parkinsonien atypique, le DaTSCAN™ peut apporter une contribution au diagnostic précoce. Si le retard au diagnostic n'a pas d'incidence sur l'évolution naturelle de ces maladies, il est mal vécu par les patients et leur famille et entraîne des coûts supplémentaires. Le diagnostic précoce permet parfois de soulager un patient qui répondrait à la thérapeutique spécifique.

Le DaTSCAN™ est indiqué dans le diagnostic différentiel d'un tremblement essentiel, le diagnostic différentiel entre une maladie d'Alzheimer et la maladie à corps de Lewy. Le DaTSCAN™ permet d'estimer une composante dégénérative éventuelle devant un syndrome extrapyramidal chez un patient sous neuroleptiques.

Si une analyse visuelle suffit le plus souvent pour répondre au clinicien sur la présence ou l'absence d'une atteinte et sa sévérité, elle n'est pas spécifique de la pathologie sous-jacente. L'examen est d'autant plus informatif qu'une analyse semi-quantitative est réalisée, par comparaison avec une base de données normale en fonction de l'âge. Dans tous les cas, un prérequis à l'analyse suppose un réalignement optimal des images.

Dans ces pathologies complexes, parfois multifactorielles, une orientation diagnostique peut être proposée si l'on dispose d'une imagerie hybride associant un scanner X qui permet d'inclure les informations morphologiques dans l'interprétation (atrophie, séquelles ischémiques...). Une aide supplémentaire est apportée par la double scintigraphie associant l'imagerie de perfusion et le DaTSCAN™ qui est réalisée simultanément. ■

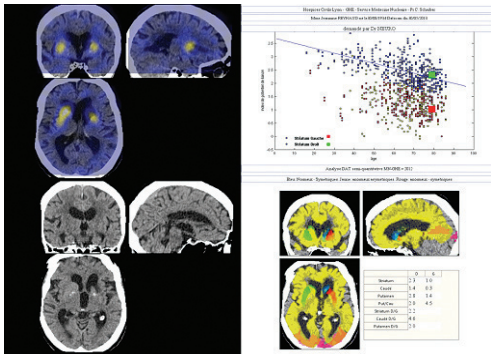

Figure 18 : examen DaTSCAN™ d'un patient présentant un syndrome Parkinsonien secondaire à un accident vasculaire ischémique Sylvien gauche profond ayant détruit une partie du striatum. Le clinicien souhaitait éliminer la coexistence d'une maladie dégénérative. La valeur strictement normale du striatum droit est en faveur d'une intégrité de la voie dopaminergique droite. Le syndrome Parkinsonien est secondaire à l'accident vasculaire.

Wei He,
M.D., PH. D.,
Director of nuclear medicine departement and PET/CT Center Fu Dan University, affiliated with Shanghai Hua Dong Hospital China

新型SPECT肺通气灌注三维定量分析在预测肺癌患者肺叶切除术后残余肺功能的临床价值

新型**SPECT**肺通气灌注三维定量分析在预测肺癌患者肺叶切除术后残余肺功能的临床价值

【摘要】 目的 探讨新型**SPECT**肺通气灌注三维（**3D**）定量分析预测肺癌患者肺叶切除术后残余肺功能的能力。 方法 对拟在我院行肺叶切除术的**80**名肺癌患者，术前**1**个月内行常规肺功能，高分辨率**CT**和**SPECT**肺通气灌注扫描检查。肺功能以第**1**秒用力呼气容积（**FEV1L**）表示。对**SPECT**肺通气灌注扫描资料分别进行**2D**和**3D**定量分析，根据获得的数值，相应计算术后肺功能的公式，得出**FEV1L**预测值，配对进行**t**检验，并与手术后**2-3**个月患者常规肺功能复查的实测值进行配对**t**检验、**Pearson**相关性检验和**Bland-Altman**一致性分析。结果 **2D**灌注预测值与**3D**灌注预测值，**2D**通气预测值与**3D**通气预测值比较差别均有统计学意义（**P<0.05**）。**2D**灌注预测值与**2D**通气预测值，**3D**灌注预测值与**3D**通气预测值比较差别均无统计学意义。**FEV1L**预测值与术后实测值比较差别均有统计学意义（**P<0.05**）。**2D**灌注预测值、**2D**通气预测值、**3D**灌注预测值、**3D**通气预测值与术后实测值相关系数 **r** 值分别为：**0.711**、**0.695**、**0.884**、**0.862**（**P<0.05**）。**Bland-Altman**—致分析结果：**2D**灌注预测值、**2D**通气预测值、**3D**灌注预测值、**3D**通气预测值与术后实测值差值的平均值和一致性界限分别为**-0.346L(-0.899L,0.313L)**、**-0.323L(-1.075L,0.469L)**、 **-0.293L(-0.801L, 0.109L)**、 **-0.303L(-0.811L, 0.165L)**。 结论 新型**SPECT**肺通气灌注三维（**3D**）定量分析创新新型混合式**3D**肺叶定量**SPECT**肺通气预测肺癌患者肺叶切除术后残余肺功能的结果与手术后肺功能实测值之间有较强的相关性和一致性，较传统**2D**定量分析预测值更准确，可能作为预测肺叶切除术后呼吸功能的手段。

【关键词】 肺癌； 肺叶切除术； 体层摄影术；单光子发射型计算机断层扫描； 呼吸功能预测



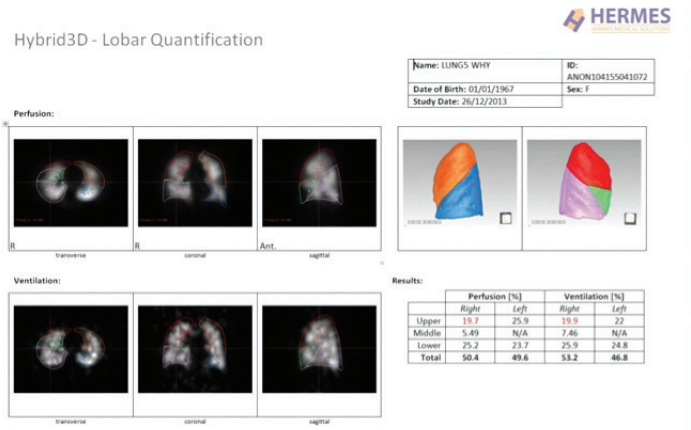

方法	T值	P值（配对T检验）
2D 灌注 VS 2D 通气	0.605	>0.05
3D 灌注 VS 3D 通气	0.860	>0.05
2D 灌注 VS 3D 灌注	2.145	<0.05
2D 通气 VS 3D 通气	2.038	<0.05

Dr. Jun Hatazawa, M.D., Ph.D.,
President of the AOFNMB, Japan

NUCLEAR BRAIN IMAGING IN MEDICAL PRACTICE IN JAPAN

BASIS OF NUCLEAR BRAIN IMAGING

Brain is an organ by which we can perceive, exercise, learn, remember, think, behave and imagine among other tasks. To fulfill its functions, the brain exclusively metabolizes glucose to produce energy in the form of adenosine triphosphate (ATP) by oxidative glycolysis. Half of the ATP is used for the electrical activity of the neurons, and the other half is consumed for the synthesis and catalysis of brain tissue components. ^{18}F fluoro-deoxy-glucose (^{18}F FDG) PET imaging (figure 1) demonstrates very nicely the that that the human brain consumes more glucose than any other organ of the body. The human brain consumes approximately 100-150g of glucose per day.

Brain function is maintained by a continuous supply of glucose and oxygen by the cerebral circulation. The Cerebral Blood Flow (CBF) is tightly controlled to supply the brain with the necessary amount of glucose and oxygen needed to perform its functions. Over the past few decades the scintigraphy mapping of the CBF has been used to determine and evaluate the activation of the different areas of the brain while performing various tasks such as speech, calculation, memory, and exercise (figure 2).

Figure 1

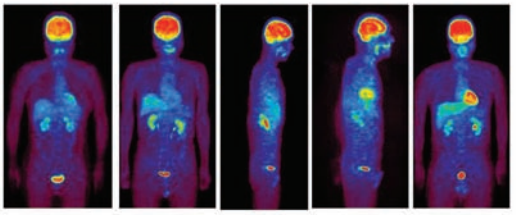

Figure 1. Whole body PET images 1 hour after intravenous administration of F-18 fluoro-deoxy-glucose (FDG) in five different normal volunteers. All subj showed high FDG uptake to their brain. Myocardial uptake was found when blood glucose level was high. FDG is excreted from urinary system.

BRAIN STROKE

Brain is very sensitive to CBF reduction because of the need of a continuous and uninterrupted supply of glucose and oxygen. Brain perfusion imaging in nuclear medicine is now employed to detect CBF change in central nervous system diseases. Stroke is the most common neurological disease in adults and can be fatal. In acute ischemic stroke due to embolic occlusion of carotid artery or major cerebral arteries, CBF suddenly decreases to less than 50% of normal level. Patients complain of difficulty of motion, sensory loss, and finally consciousness disturbance. Even in such situation, the brain can still extract glucose and oxygen as much as possible from decreased CBF, and can survive during 6 hours of onset (figure 3). If the blood clot is resolved within 6 hours of onset, recirculation can minimize ischemic brain damage or rescue completely without any neurological symptoms (figure 4).

In chronic ischemic stroke due to atherosclerotic stenosis of major cerebral arteries, CBF is gradually decreased. Patients first complain of transient motion and/or sensory disturbance for several minutes once a month, followed by more frequent onset and longer duration. It indicates high probability of impending

Figure 2

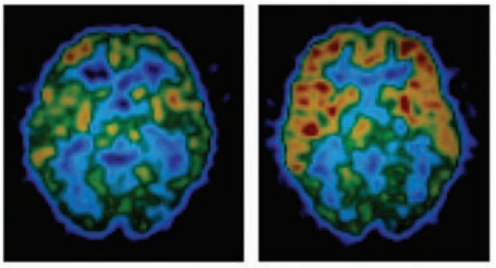

Figure 2. Tomographic FDG PET images in single normal volunteer. Left imag was obtained under resting condition during any specific thinking. Right imag was obtained under resting condition during imagining bright future of life. Positive thinking was associated with bilateral frontal lobe activation.

Figure 3

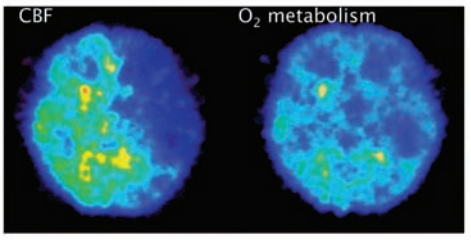

Figure 3. Cerebral Blood Flow (CBF) (left) and Cerebral Oxygen Consumption (right) in a patient with acute embolic occlusion of left internal carotid artery s within 6 hours of onset. CBF and oxygen consumption was measured by inhala of $C^{15}O_2$ and $^{15}O_2$, respectively. CBF was decreased to less than 50% of Contralateral hemisphere, but oxygen metabolism was maintained.

Figure 4

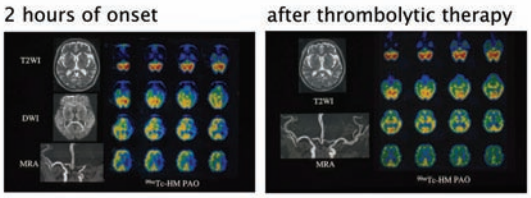

Figure 4. This patient showed sudden onset of right hemiparesis and consciousn Disturbance. MRA indicated left middle artery occlusion without any signal chan MR T2WI and diffusion weighted images 2 hours of onset. 99mTc-HMPAO SPEC brain perfusion imaging showed 50% reduction of CBF. Acute thrombolytic thera by recombinant tissue plasminogen activator resulted in immediate recanalizati recovery of CBF without ischemic brain injury.

Figure 5

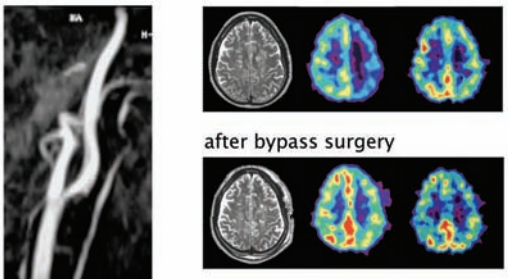

Figure 5. MR angiography indicated severe stenosis of left carotid artery. CBF was decreased by 40% with normal oxygen metabolism (upper row). After bypass, CBF was normalized (bottom row).

cerebral infarction with irreversible neurological deficits. Brain perfusion SPECT provides information on the severity of circulation disturbance before the onset of cerebral infarction and a guide for therapy strategy such as interventional reconstruction of stenotic artery, surgical removal of atheroma in thick arterial wall, or extra cranial-intracranial bypass surgery (Figure 5).

EPILEPSY

Epilepsy is one of the major neurological diseases in children. Most patients are treated with anti-epileptic medications, but around 10% of epileptic children needs further treatment such as surgical removal of epileptogenic foci. During epilepsy, epileptogenic lesion shows abnormally increased CBF. Brain perfusion SPECT is employed to localize epileptogenic foci in patients with intractable epilepsy for surgical removal (Figure 6).

ALZHEIMER'S DISEASE

While aging, people experience forgetfulness. At the very early stage of Alzheimer's disease (AD), patients complain of memory impairment. It is difficult to distinguish Alzheimer's symptoms from physiological forgetfulness. Brain Perfusion Imaging in patients with cognitive impairment is now employed to categorize among AD, frontotemporal

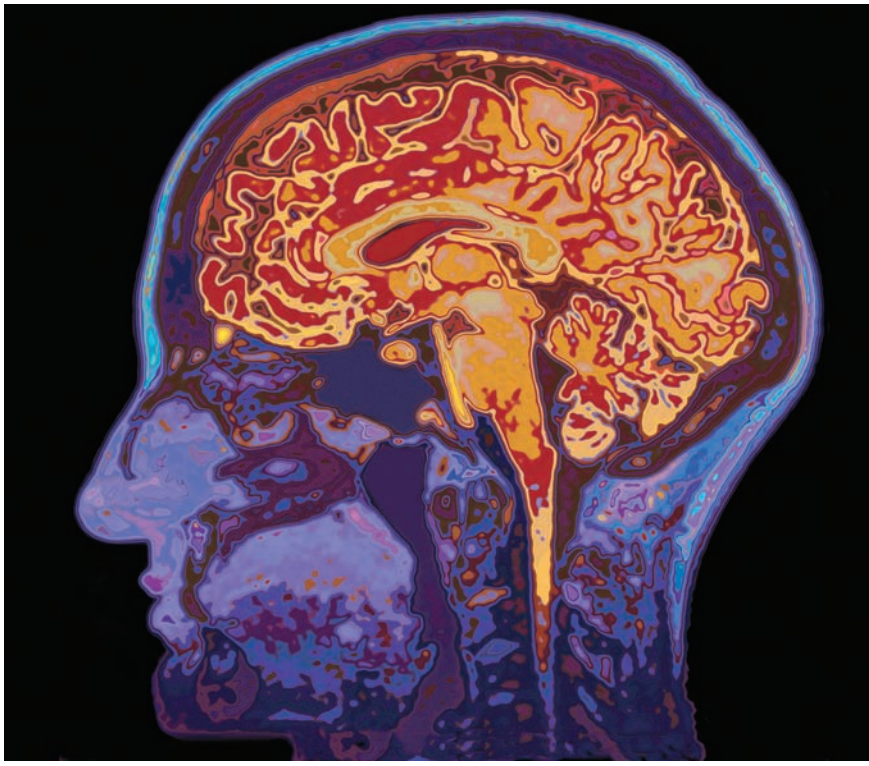

dementia, dementia with diffuse levy body disease, and other types (figure 7). Histopathological prediction of CNS diseases using PET/CT is now extending to Alzheimer's disease where β-amyloid and tau protein deposition is visualized.

PARKINSON'S DISEASE

Brain functions require the sophisticated integration of neuronal signals among population of neurons. Communication among neurons is done by releasing chemical compounds called neurotransmitters released by a neuron and binding to another. Neuron to neuron communication failure happens due to neurotransmitter "dopamine" deficiency in Parkinson's disease (figure 8), "acetylcholine" deficiency in Alzheimer's disease, and "serotonin" deficiency in major depression. DatSCAN is a new SPECT tracer that enables the diagnostic of Parkinson's disease (see Dr. Christian Scheiber article in this issue).

Figure 6

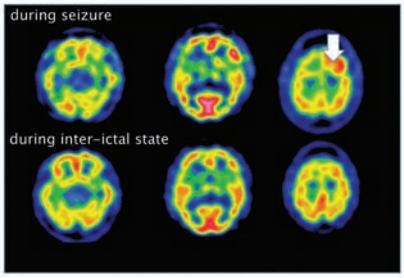

Figure 6. Tc-99m ECD brain perfusion imaging in a patient with intractable epilepsy. Upper row images were obtained during seizure, and bottom row images were obtained during no seizure confirmed by electro-encephalograp The arrow indicates increased CBF during seizure indicating epileptogenic focus.

Figure 7

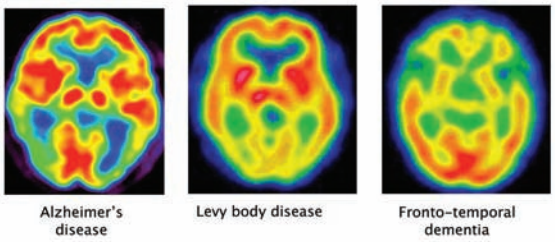

Figure 7. In patients with cognitive impairment, regional reduction of glucose metabolism is a diagnostic marker of Alzheimer's disease (left, temporal lobe diffuse Levy body disease (center, temporal lobe and occipital lobe), and fron temporal dementia (right, frontal lobe and temporal lobe).

Figure 8

Dopaminergic System Imaging

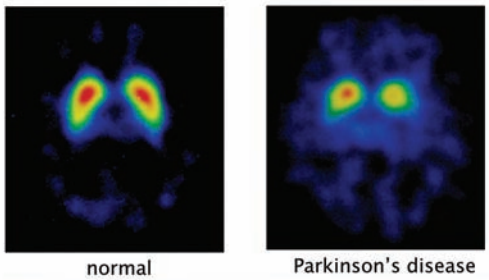

Figure 8. ^{123}I–β–CIT SPECT images in normal subject (left) and in a patient with Parkinson's disease (right). Reduction of ^{123}I–β–CIT indicated a failure o dopaminergic signal transduction from substantia nigra to putamen in Parkinson's disease (right).

BRAIN TUMOR

Brain tumor is one of the most dreadful diseases in adults and children. The therapeutic strategy is usually determined by histo-pathological classification according to World Health Organization grading. Biopsy of brain tumor is invasive because of transcranial tissue sampling. ^{18}F-FDG or ^{11}C-Methionine PET/CT is an alternative way to evaluate, non-invasively, the histopathological malignancy of cerebral gliomas non-invasively (figure 9).

NUCLEAR BRAIN IMAGING IN JAPAN

In Japan, one million and eighty thousand nuclear medicine studies are performed every year (National Survey of Nuclear Medicine Practice, Japan Radioisotope Association) using single photon isotopes on planar and SPECT cameras. Two hundred and fifty thousand of these studies, i.e. 22% are for brain imaging. Ischemic stroke, Parkinson's syndrome, cognitive impairment, epilepsy, head injury (especially after traffic accident), and brain tumor are the major indications. The cost of the study is approximately $400~500 US. Our national insurance system covers 70% of the cost and patients pay about 30%.

BONE SCINTIGRAPHY (30%) AND MYOCARDIAL PERFUSION IMAGING (22%)

Compared to other countries and other nuclear medicine studies (bone scintigraphies and cardiac studies represent 30% and 22% respectively), in Japan is the availability and the widespread use of dedicated brain SPECT software such as eZIS (Dr. Hiroshi Matsuda and his colleagues) and iSSP (Dr. Satoshi Minoshima and his colleagues). In patients with cognitive impairment, hypo-perfusion is detected on a pixel-by-pixel and compared to a normal data base (Figure 10). It is objective, comprehensive, and reproducible for nuclear medicine physicians, referring doctors, and patients.

CONCLUSION

Nuclear brain imaging with SPECT and PET in Japan is a significant part of the nuclear medicine practice. It is applied to various brain disorders to detect physiological and metabolic abnormality before morphological changes become evident. The availability and use of performant and reliable analytical software is a significant factor for the success of brain imaging. ■

Figure 9

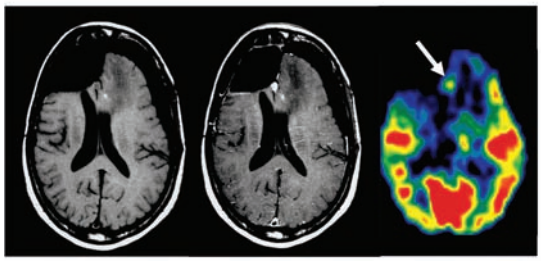

Figure 9. Non-contrast (left) and contrast (center) MR images and FDG PET image (right) after surgical removal of cerebral glioma. Small nodule located in resection border showed high uptake of FDG indicating residual tumor.

Figure 10

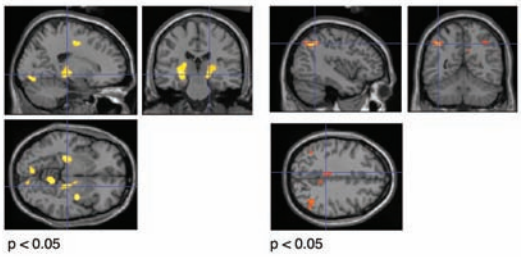

Figure 10. Statistical parametric analysis of forgetfulness (left) and Alzheimer' disease (right) by SPECT brain perfusion imaging. Forgetfulness showed bilate hippocampal hypoperfusion, while Alzheimer's disease showed hypoperfusion bilateral parietal lobes, posterior cingulate gyrus, and precuneus.

WORLD FEDERATION OF NUCLEAR MEDICINE AND BIOLOGY

Leadership

COMPOSITION and ELECTION

The Executive Board is the highest executive level of the Federation. It shall create a vision for the future of the Federation and develop strategies to fulfil them as well as to develop strategies regarding the cooperation with partner societies for the future of the medical specialty and the benefit of its Members and national Member societies.

It shall execute and supervise the execution of operational goals along the strategic lines as developed together with the different Integral Parts of the Federation. The Executive Board represents the Federation legally and is responsible for its financial management according to the Statutes and legal regulations.

Candidates for the position of President Elect, Secretary General and Treasurer will be proposed by the Members and elected during the General Assembly.

EXECUTIVE BOARD

Lizette Louw
PRESIDENT

Savvas Frangos
PRESIDENT-ELECT

Francois Lamoureux
TREASURER

Gopinath Gnanasegaran
GENERAL SECRETARY

Jean Luc Urbain
Immediate Past-President

Munir Ghesani
SNMMI PRESIDENT

Rudi A.J.O. Dierckx
EANM PRESIDENT

Hee-Seung Bom
ARCCNM PRESIDENT

Gang Huang
AOFNMB PRESIDENT

Fernando Faccio
ALASBIMN PRESIDENT

Salah Eddine Bouyoucef
AANM PRESIDENT

Roslyn Francis
ANZSNM PRESIDENT

Mohamad Haider
ARSNM PRESIDENT



Diana Paez
IAEA REPRESENTATIVE

John Prior
WHO REPRESENTATIVE



Patricia Bernal
2026 CONGRESS PRESIDENT

CANM ACMN

The Canadian Association of Nuclear Medicine
Association canadienne de médecine nucléaire

BOARD OF DIRECTORS / CONSEIL D'ADMINISTRATION

President,
Dr. François Lamoureux,
président

Past President,
Dr. Andrew Ross,
président sortant

Vice-President,
Dr. Jean-Luc Urbain,
vice-président

Secretary-Treasurer,
Dr. Jonathan Boekhoud
secrétaire-trésorier

Member-at-Large,
Dr. Jonathan Abele,
membre à titre personnel

Member-at-Large,
Dr. Salem Yuoness,
membre à titre personnel

Member-at-Large,
Dr. Kamel Hasan, Olfat,
membre à titre personnel

Member-at-Large,
Dr. Philip Cohen,
membre à titre personnel

Member-at-Large,
Dr. Norman Laurin,
membre à titre personnel

Member-at-Large,
Dr. Glenn Ollenberger,
membre à titre personnel

Member-at-Large,
Dr. Antoine Leblond,
membre à titre personnel

Member-at-Large,
Dr. Anita J Thomas,
membre à titre personnel

Member-at-Large,
Dr. Cheryl Lynn Jefford
membre à titre personnel

Member-at-Large (invited),
Dr. Lionnel Zuckier
membre à titre personnel (invité)

Member-at-Large,
Dr. Peter Maliha
membre à titre personnel

Member-at-Large,
Dr. Christopher O'Brien,
membre à titre personnel

Member-at-Large, (Resident)
Benoit Nolet, membre à titre
personnel

THE CANM

✓ Its dedication to promote the **transfer of scientific bench discoveries** into molecular & personalized medical diagnostics and therapies.

✓ Its ability to **promote, develop and support** the use of medical isotopes **in the emerging countries**.

✓ Its proven commitment to educate and provide **high level training** to nuclear medicine professionnals from across the world, **particularly from emerging countries** in collaboration with the **Royal College of Canada**.

✓ **The Pangea** project.

THE PANGEA PROJECT

ePATIENT
NUCLEAR MEDICINE & MOLECULAR IMAGING

- Promoting nuclear medicine • Continuous training
- Education / Teaching around the world

PANGEA
nmpangea.com

Nicolas Rondeau Lapierre

INFO CONTACT
General manager / Directeur général
Canadian Association of Nuclear Medicine /
Association canadienne de médecine nucléaire

canm@canm-acmn.ca
www.canm-acmn.ca
1.514.963.3269

CANM ACMN

CANM ACMN

2023 ANNUAL SCIENTIFIC CONFERENCE

CONFÉRENCE SCIENTIFIQUE ANNUELLE 2023

From October 19 - 21 2023
At the Brookstreet Hotel
Ottawa, ON

More information to come. Stay tuned

CANM ACMN | The Canadian Association of Nuclear Medicine
Association canadienne de médecine nucléaire

INTERNATIONAL CONFERENCES

AMSMNQ	10-12 mai 2024	Québec
SNMMI	8-11 june 2024	Toronto
Swiss Congress MN	20-22 june 2024	Geneva
EANM	19-23 october 2024	Hambourg
ALASBIM	November 2023	Argentina
WFNMB	2026	Cartagena

SAVE THE DATE :
CANM - October 19-21st
OTTAWA

The Canadian Association of Nuclear Medicine strives for excellence in the practice of diagnostic and therapeutic nuclear medicine by promoting the continued professional competence of nuclear medicine specialists, establishing guidelines of clinical practice, and encouraging biomedical research. We work with all professionals in nuclear medicine to ensure that Canadians have access to the highest quality nuclear medicine services.

SISTER ORGANIZATIONS

SNMMI Society of Nuclear Medicine and Molecular Imaging · EANM European Association of Nuclear Medicine · World Federation of Nuclear Medicine and Biology · AIPES · ARCENM · ASNC · ARSNM Arab Society of Nuclear Medicine · AFNMB · IAEA International Atomic Energy Agency · alasbimn · South African Society of Nuclear Medicine · SFMN

CANM 2023 SPONSORS - PARTENAIRES ACMN 2023

AAA - Novartis
Bayer
Curium
Cyclomedica
GE Healthcare
Isologic
Hermes Medical Solutions
Lantheus
Siemens

CANM ACMN

canm@canm-acmn.ca
www.canm-acmn.ca
1.514.963.3269

Facebook de l'AMSMNQ
AMSMNQ Facebook

VENEZ CONSULTER

https://www.facebook.com/AMSMNQ/

Venez consultez la page Facebook de l'association des médecins spécialistes en médecine nucléaire du Québec. Vous y trouverez de multiples informations concernant principalement la médecine nucléaire québécoise.

Nous y partageons des événements à venir, des articles intéressants et toutes nouvelles susceptibles d'intéresser la communauté de médecine nucléaire d'ici et d'ailleurs. Nous sommes aussi très fier de présenter les réalisations exceptionnelles de certains de nos membres.

N'hésitez pas à nous contacter si vous souhaitez nous partager une bonne nouvelle, une information, ou un article d'intérêt.


Dr. Khun Visith Keu
Dr. Karine Provost
Responsable de la page Facebook de l'AMSMNQ

Cher lecteur,

Avec le support constant de la vice-présidente du comité, Dr Ophélie Bélissant et des autres membres du comité, nous organisons plus d'une vingtaine d'heures de formation médicale continue annuellement. L'activité principale est le colloque tenu au mois de mai en rotation dans les différentes régions du Québec. Nous organisons une dizaine de clubs de lecture par année en formule WEB pour permettre aux membres de discuter cordialement d'articles d'intérêts. Finalement, des webinaires thématiques sont ajoutés ponctuellement pour combler des besoins plus précis. Une série de webinaires sur la thérapie aux radioligands du PSMA est d'ailleurs prévue l'automne prochain. Plusieurs activités sont présentées sous forme de programmes interactifs d'auto-évaluation ou de simulation.

Les activités se déroulent habituellement en français mais les présentateurs anglophones intéressés à participer sont bienvenus! Pour plus d'information, visitez régulièrement le site WEB de l'AMSMNQ ou abonnez-vous à sa page Facebook.


Dr Sylvain Prévost
Président du comité de DPC de l'AMSMNQ
Spécialiste en médecine nucléaire, CHUS
Professeur d'enseignement clinique, Université de Sherbrooke

Dr Ophélie Bélissant
Vice-présidente du comité de DPC de l'AMSMNQ

ASSOCIATION DES MÉDECINS SPÉCIALISTES EN MÉDECINE NUCLÉAIRE DU QUÉBEC

AMSMNQ

L'IMAGERIE PERSONNALISÉE PAR LA MÉDECINE NUCLÉAIRE

« La mission du comité de développement professionnel continu (DPC) de l'Association des médecins spécialistes en médecine nucléaire du Québec (AMSNMQ) est de soutenir les médecins nucléistes à acquérir et à préserver leur expertise médicale, ainsi qu'à améliorer leurs compétences de collaboration et de communication dans le but de prioriser la qualité des soins aux patients. »

COMITÉ EXÉCUTIF

Dr. Norman Laurin
Président

Dr. Frédéric Arsenault
Trésorier

Dr. Karine Provost
Conseillière

Dr. Anthony Ciarallo
Secrétaire

Dr. Éric Turcotte
Conseillier



Dr. Francois Lamoureux
Président sortant (invité)

Dr. Khun Visith Keu
Conseillier

ORGANISATIONS

ACOMEN • American Society of Nuclear Cardiology • Association Canadienne de Médecine Nucléaire • Association Chinoise de Médecine Nucléaire • British Nuclear Medecine Society • Cancer de la Thyroïde Canada • Commission Canadienne de Sureté Nucléaire • Collège des Médecins du Québec • Collège Royal des Médecins et Chirurgiens du Canada • European Association of Nuclear Medecine • Fédération de Médecins Spécialistes du Québec • Fondation Canadienne de la Thyroïde • International Atomic Energy Agency • Pubmed • Société Française de Médecine Nucléaire et d'Imagerie Moléculaire • Society of Nuclear Medecine • Société Canadienne du Cancer • Université McGill • Université de Montréal • Université de Sherbrooke • World Federation of Nuclear Medicine and Biology

PARTENAIRES

Hermes Medical Solutions • Lantheus • Siemens Santé Limitée • GE Molecular Healthcare • Curium • Jubilant-DraxImage • Isologic • Philips • Segami • Cyclomedica • Financières des Professionnels • Sogemec

NOUS JOINDRE

Madame Nathalie Guerra
Directrice administrative

Téléphone : (514) 350-5133 ou 1-(800)-561-0703
Télécopieur : (514) 350 -5151
Courriel : amsmnq@fmsq.org

2, Complexe Desjardins, porte 3000
C.P. 216 , succursale Desjardins
Montréal (Québec) Canada H5B 1G8

AMSMNQ

medecinenucleaire.com
www.facebook.com/AMSMNQ/

INTRODUCING PLUVICTO™

PLUVICTO™ is the first and only PSMA-targeted radioligand therapy indicated in adults with PSMA+ mCRPC available in Canada[1,2]†

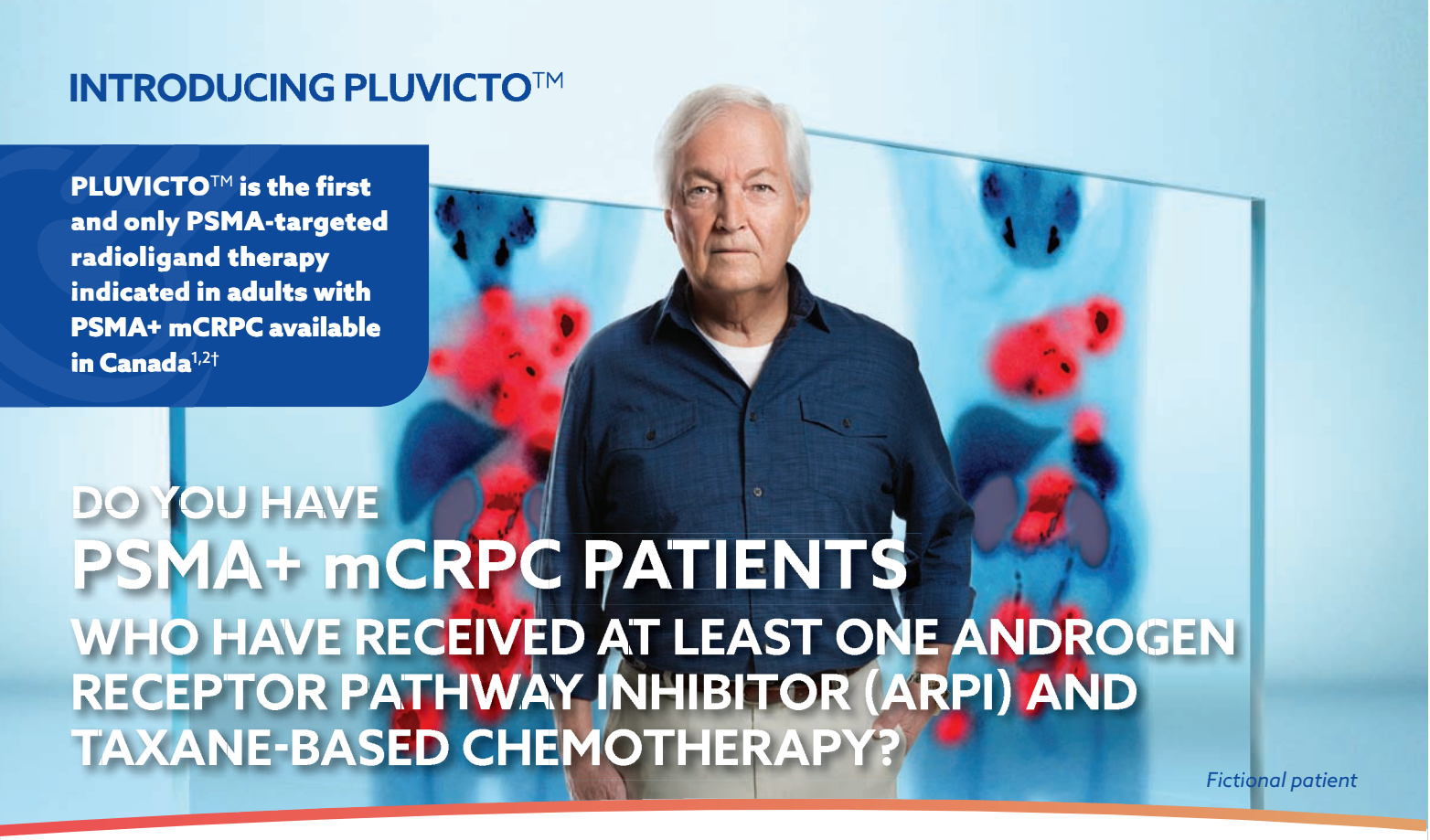

DO YOU HAVE PSMA+ mCRPC PATIENTS WHO HAVE RECEIVED AT LEAST ONE ANDROGEN RECEPTOR PATHWAY INHIBITOR (ARPI) AND TAXANE-BASED CHEMOTHERAPY?

Fictional patient

PLUVICTO™ (lutetium [^{177}Lu] vipivotide tetraxetan injection) is indicated for the treatment of adult patients with PSMA-positive mCRPC who have received at least one androgen receptor pathway inhibitor (ARPI) and taxane-based chemotherapy.

The VISION trial demonstrated a statistically significant improvement in both major efficacy outcome measures of OS and rPFS by BICR with PLUVICTO™ plus BSoC compared to treatment with BSoC alone, respectively.[1‡]

- OS: estimated 38% reduction in the risk of death based on the HR (HR=0.62; 95% CI: 0.52, 0.74; $P<0.001$); median OS 15.3 months vs. 11.3 months[1]
- rPFS: HR for progression or death, 0.40; 99.2% CI, 0.29 to 0.57; $P<0.001$ (significance level, 0.008); median rPFS 8.7 months vs. 3.4 months[3]

Interpretation of the magnitude of the rPFS effect was limited due to a high degree of censoring from early drop out in the control arm.[1]

Refer to the page in the bottom-right icon for additional safety information and for a web link to the product monograph discussing

- Most serious warnings and precautions regarding healthcare professional qualifications pertaining to use of radiopharmaceuticals; severe and life-threatening myelosuppression and renal toxicity including severe renal injury
- Other relevant warnings and precautions regarding location of use; compliance with regulations and good safety practices related to radiopharmaceuticals; contamination including special precautions such as bladder catheterization in incontinent patients; radiation exposure including long-term cumulative radiation exposure and increased risk for cancer; patient counselling on consumption of oral fluids and voiding to reduce bladder radiation; patient education regarding minimizing radiation exposure; hematology laboratory tests to assess myelosuppression; dose adjustments and discontinuation related to severity of myelosuppression; renal toxicity; kidney function laboratory tests; dose adjustments and discontinuation based on the severity of renal toxicity; male reproductive health; risk of temporary or permanent infertility; use effective contraception; no indication in pregnant women and risk of fetal harm in pregnant women
- Conditions of clinical use, adverse reactions, drug interactions, and dosing instructions.

In addition, the page contains the reference list and study parameters relating to this advertisement.

PSMA=prostate-specific membrane antigen; mCRPC=metastatic castration-resistant prostate cancer; BSoC=best standard of care; BICR= blinded independent central review; HR=hazard ratio; OS=overall survival; rPFS=radiographic progression-free survival

† Comparative clinical significance has not been established.

PLUVICTO™
lutetium (^{177}Lu) vipivotide tetraxetan injection

Indication and clinical use:

PLUVICTO™ (lutetium [^{177}Lu] vipivotide tetraxetan injection) is indicated for the treatment of adult patients with PSMA-positive mCRPC who have received at least one androgen receptor pathway inhibitor (ARPI) and taxane-based chemotherapy.

Pediatrics (<18 years of age): No data are available to Health Canada; therefore, Health Canada has not authorized an indication for pediatric use.

Geriatrics (≥65 years of age): No clinically relevant differences in efficacy were observed between patients ≥65 years and those younger than 65 years.

Most serious warnings and precautions:

Healthcare professional qualifications: Radiopharmaceuticals should be used only by those health professionals who are appropriately qualified in the use of radioactive prescribed substances in or on humans.

Myelosuppression can occur in patients treated with PLUVICTO™. PLUVICTO can cause severe and life threatening myelosupression including anemia, thrombocytopenia, leukopenia and neutropenia.

Renal toxicity can occur in patients treated with PLUVICTO™. Cases of severe renal injury have been reported.

Other relevant warnings and precautions:

- Location of use; compliance with regulations and good safety practices related to radiopharmaceuticals
- Contamination: the following measures should be taken for 2 days after receiving the radiopharmaceutical product:
  - Toilet should be used instead of urinal
  - Toilet should be flushed several times after use
  - Contamination: special precautions such as bladder catheterization should be taken following administration to incontinent patients to minimize the risk of radioactive contamination
- Radiation exposure including long-term cumulative radiation exposure is associated with an increased risk for cancer
- Radiation exposure to patients, medical personnel, and household contacts should be minimized during and after treatment
- Encourage patients to increase consumption of oral fluids and voiding to reduce bladder radiation
- Patient education regarding minimizing radiation exposure to patient and others including instruction about close contact, sexual activity and sleeping location
- Hematology laboratory tests before and during treatment to assess myelosuppression; PLUVICTO™ should be withheld, dose reduced, or permanently discontinued and patients should be clinically managed as deemed appropriate based on the severity of myelosuppression
- Renal toxicity; maintain hydration; frequent urination before and after administration; perform kidney function laboratory tests before and during treatment; withhold, reduce dose or permanently discontinue based on the severity of renal toxicity
- Male reproductive health; risk of temporary or permanent infertility; use effective contraception during treatment with PLUVICTO™ and for 14 weeks after the last dose
  PLUVICTO™ is not indicated in females; risk of fetal harm if used in pregnant women

For more information:

Consult the Product Monograph at **https://www.adacap.com/wp-content/uploads/pluvicto-pm-20220825-en.pdf** for adverse reactions, drug interactions and dosing information which have not been discussed in this piece. The Product Monograph is also available by calling 1-800-363-8883.

‡ VISION was an international, prospective, open-label, multicenter, randomized phase 3 clinical trial evaluating PLUVICTO™ in 831 adult patients with PSMA-positive mCRPC previously treated with at least 1 ARPI and 1 or 2 taxane regimens. Participants were randomized in a 2:1 ratio to receive PLUVICTO™ (7.4 GBq every 6 weeks for up to 6 cycles) + BSoC or BSoC alone.

References: 1. PLUVICTO™ Product Monograph. Advanced Accelerator Applications USA, Inc. August 25, 2022. **2.** Data on file. **3.** Sartor O et al. Lutetium-177–PSMA-617 for Metastatic Castration-Resistant Prostate Cancer. *NEJM* 2021;385:1091-103.

Advanced Accelerator Applications
A Novartis Company

Pluvicto™ is manufactured by Advanced Accelerator Applications USA, Inc. and is imported and distributed in Canada by Quality & Compliance Services Inc. for Advanced Accelerator Applications Canada, Inc.
Advanced Accelerator Applications, A Novartis Company
2810 Matheson Blvd East, Suite 700
Mississauga, Ontario, L4W 4 X7 Canada

REVIEWED BY PAAB

MEMBER OF INNOVATIVE MEDICINES CANADA

PLUVICTO™
lutetium (^{177}Lu) vipivotide tetraxetan injection

Éric Turcotte, MD, FRCPC

Spécialiste en Médecine Nucléaire
Chef Clinique, Centre d'Imagerie Moléculaire de Sherbrooke (CIMS)
Professeur agrégé, Université de Sherbrooke

POSITRON EMISSION TOMOGRAPHY (PET)

Positron Emission Tomography (PET) is a cutting edge, non-invasive, diagnostic imaging technique which allows the measurement of biochemical processes or the expression of cellular receptors by the use of positron-emitting radioactive tracers. The imaging tracers most often contain atoms naturally found in organic molecules, but in the form of radioactive analogues of Oxygen (^{15}O), Nitrogen (^{13}N), Carbon (^{11}C) or Fluorine (^{18}F) atoms.

Developed during the 70s to study the normal and pathological brain function, in the 90s, PET became an important clinical tool for oncological imaging following the demonstration of its usefulness in the detection of several cancer types.

Initially confined to research centers, PET has spread rapidly since 1998 to the vast majority of important oncologic centers in industrialized countries. Since 2001, PET has been paired to axial computed tomography (CT) (Figure 1) in order to better locate lesions by relation to the anatomical structures. It also facilitates the interpretation of results by improving the specificity and, furthermore, combined PET/CT data allows the planning of radiation therapy treatment. PET/CT images also have a considerable advantage for planning the surgical approach, since an accurate anatomical localization may be established. It is also possible to merge any PET study to any three-dimensional imaging including MRI and SPECT tomography, even if they have been obtained on different devices or at different times (Figure 2).

Gradually, the price of PET/CT devices has dropped by half and now can be purchased for 1.2M$. The scanner allows the accomplishment of a full study from the neck to the pelvis in less than 25 minutes, thus improving considerably the productivity of PET and helping to reduce the cost of each exam (throughput of 15-20 exams per scanner per 8 hours). Since 2005, PET/CT technology deployed quickly in the public and the private health systems across Canada. However, in 2014, access to PET is very different from east to west provinces and Canada is still behind many developed countries. Quebec is by far the province providing the best access to this technology. Quebec is also the first province which has deployed the latest generation of PET/CT devices to regional hospitals away from academic and research centers.

As with the studies performed in conventional nuclear medicine (bone or thyroid scan, myocardial perfusion, etc.), PET/CT is performed after the intravenous injection of a radioactive substance called radiotracer. Over the past few years, several radiotracers have been developed for the detection of cancer and the most important is the fluorine-18 Fluorodeoxyglucose (^{18}F-FDG). The fluorine-18, with a half-life of 110 minutes, is the isotope of choice for cancer imaging. This isotope can easily be distributed to multiple institutions and its long half-life allows it to accumulate at levels that are sufficient for imaging with adequate contrast for tumor detection. The molecule of ^{18}F-FDG is an analogue of glucose obtained by substituting a hydroxyl (-OH) group of a glucose molecule by a radioactive fluorine atom with a nucleus that contains more protons than neutrons. This atypical ratio of protons/neutrons makes the atom unstable and the latter must expel a positive charge in the form of

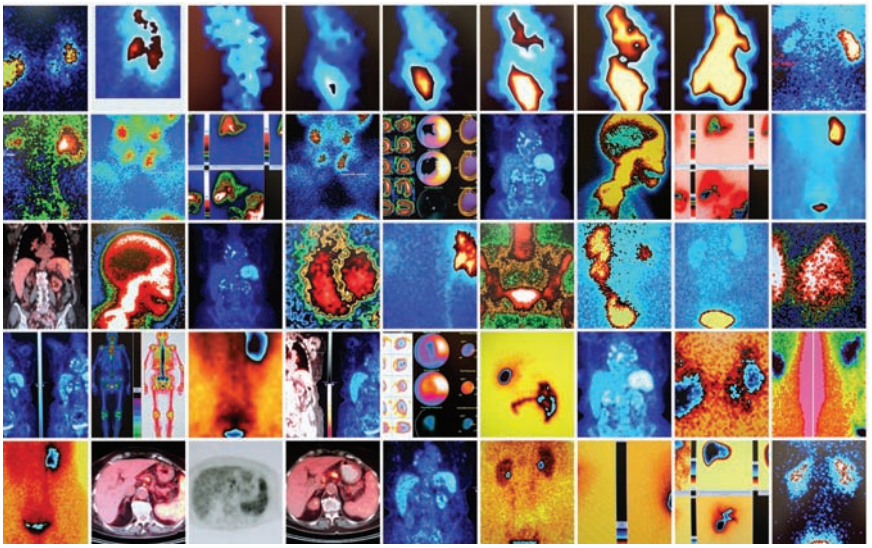

a positron to regain its stability. The PET devices are conceived to detect radioactive emissions induced by these positrons, and to precisely locate this emission inside the body. At the cellular level, the ^{18}F-FDG uses the same transmembrane carriers as glucose, and its passage is transporter – and insulin – dependent. After its entry into the cell, the ^{18}F-FDG is phosphorylated by the hexokinase, but it rapidly stops advancing into the glycolysis cascade. It thus becomes sequestered in the cell where it accumulates. The ^{18}F-FDG permits to obtain cellular information relative to the cell viability and metabolism based on the metabolic rate of the cellular glucose.

The excretion of ^{18}F-FDG is mainly through the urinary tract, regardless of if the patient is diabetic or not, because the ^{18}F-FDG molecule is not completely reabsorbed by the renal tubules, unlike glucose. There is also a certain proportion, very variable from one individual to another, which is excreted by the intestines. Figure 3 (left) shows a normal biodistribution of ^{18}F-FDG compared to the image on the right which illustrates the important consumption of ^{18}F-FDG by striated muscle due to a non-respected fasting/ glucose-free procedure. Figure 3 (right) is considered non-diagnostic. Consequently, the exam must be repeated at a later date.

The ^{18}F-FDG PET is aimed at four main fields of clinical application: oncology, cardiology (Figure 4), neurology (Figure 5) and infection/ inflammation (Figure 6). Overall, in a general hospital, more than 95 per cent of the examinations currently carried out are for oncologic indications. The rationale behind the use of ^{18}F-FDG PET in oncology is based on the increased use of glucose by the neoplastic cells, a phenomenon closely linked to the neoplastic transformation. A rapidly growing neoplasia is also ischemic in its center, hence favoring the metabolic pathway of lactic acid, which greatly increases the demand for glucose. A non-negligible proportion of the uptake also comes from the inflammatory cells surrounding the tumor. It should be noted, however, that these phenomena vary significantly depending on the type of neoplasia.

Although PET is excellent to detect neoplastic lesions, it has limitations. Some cancers have slower growth and do not substantially increase their ^{18}F-FDG accumulation and may remain undetectable (false negative). The activated neutrophils and macrophages can consume a lot of glucose and the highly inflammatory lesions can also incorporate this radiotracer (false positive). In particular, active granulomatous inflammation (tuberculosis, sarcoidosis) as well as abscesses can cause false positive results (Figure 7). Conversely, some well-differentiated cancers, such as prostate cancer, high mucinous content tumours, well differentiated neuroendocrine tumors, and certain lobular breast cancers may have a low uptake. Others, such as the hepatocarcinoma, possess phosphorylases, which allow cells to quickly eliminate the ^{18}F-FDG. A list of clinical indications for oncology PET with ^{18}F-FDG is detailed in Tables 1 and 2. Taken together, lung cancer (Figure 8) and lymphoma indications represent about 50% of the available imaging time on a PET scanner.

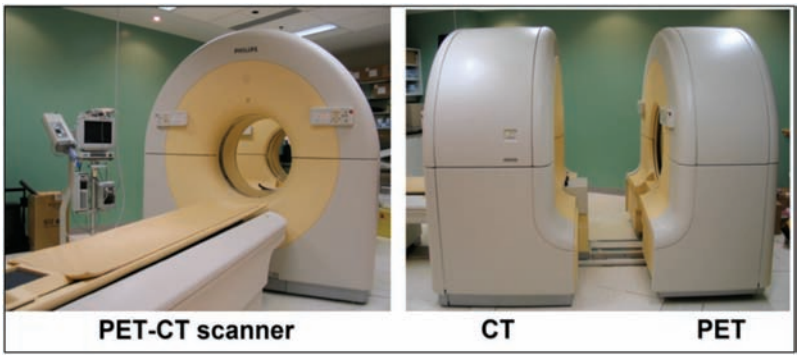

Figure 1:
PET/CT scanner allowing to sequentially obtain an axial tomography (CT) and a positron emission tomography (PET) during a same medical visit.

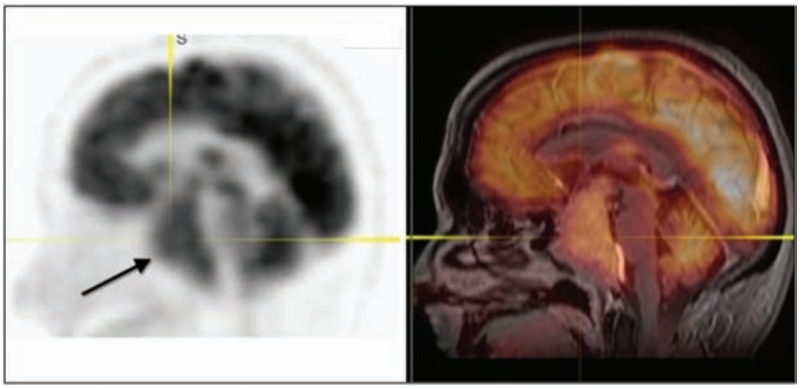

Figure 2:
Current software which enables the merging of PET not only with the CT, but with all 3D imaging modalities, including MRI. PET-MRI fusion allows better localization and characterization of the neoplastic cerebral lesions (the arrow shows a voluminous pituitary prolactinoma).

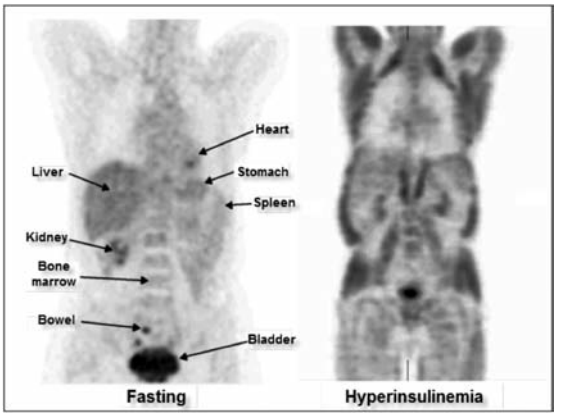

Figure 3:
PET studies performed in two different patients. The image on the left illustrates a normal biodistribution of FDG in a patient having observed the fasting procedure. The image on the right has been obtained in a patient with dextrose solute (diffuse muscle uptake induced by hyperinsulinemia).

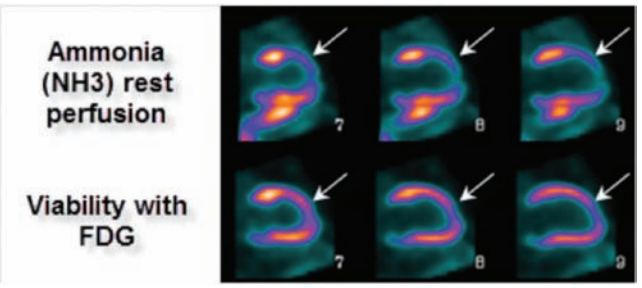

Figure 4:
This PET exam uses ammonium to assess myocardial perfusion at rest and FDG for viability. This exam is more sensitive than Thallium for the demonstration of severely ischemic regions at rest or hibernating myocardium in order to orient the therapeutic approach (to increase the ejection fraction and decrease morbidity). The example illustrates severe hypoperfusion at rest (rest ischemia) in the region of the descending anterior, completely viable on the FDG study. The study therefore suggests that this wall will resume a normal kinetic after revascularisation that will result in gain of ejection fraction.

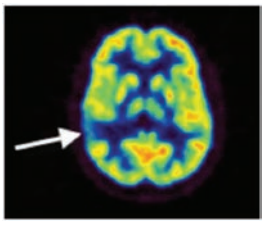

Figure 5:
Brain FDG PET in search of inter-ictal epilepsy foyers. Right temporal hypometabolism testifies to an epileptic foyer (arrow).

Table 1:

- Characterization of a mass: benign versus malignant
- Evaluation of the extension of the disease (staging and restaging)
- Orientation toward the most accessible biopsy site
- Detection of occult primary tumor site in patients with metastatic disease
- Detection of residual disease after chemotherapy/ radiotherapy or surgery
- Radiotherapy planning (delineation of gross-tumor-volume)
- Differentiation between relapse and post-surgical/ post-radiotherapy changes
- Biochemical evidence of relapse (elevated markers) without clinical signs or radiological evidences
- Follow-up or surveillance when conventional studies are equivocal or suspicious

PET should be an accessible exam to be considered by a specialist as well as the family physician. However, for a better management of the resource, it is important to recognize the strengths and weaknesses of the technique in order to ensure that the examination can answer the clinical and therapeutic dilemma. The following guiding points are to be considered if a PET/CT exam is to be requested:

Does the patient need to be fasting? Is fasting mandatory for all patients? What about diabetic patients?

Patients arriving for their exam must obey the fasting procedure (sugar-free) for at least 6 hours prior to the exam. Diabetic patients can take their oral hypoglycemic agents and their slow onset insulin dose in the morning of the examination day. However, special attention should be paid to metformin because this medication is responsible for a very intense bowel uptake (Figure 9). Thus, metformin should be stopped at least two days prior to PET if an intestinal lesion is suspected.

All sources of glucose (including lozenges, mints, gums, glucose in solution) must be strictly avoided so as to maintain circulating insulin at the basal level. If there is any doubt about the patient's glucose intake in the last six hours, the study should be deferred in order to observe fasting procedure for at least six hours (Figure 3). It is also required that the capillary blood glucose level at the time of injection is less than 10 mmol/L. If the result is higher than 10 mmol/L, one to two doses of rapid i.v. insulin can be injected in order to normalize the blood glucose level. An additional waiting period of 60 minutes is necessary to allow the exogenous insulin to be metabolized. The exam will be postponed to a later date if it is not possible to normalize the blood glucose level. It is therefore important to ensure that the diabetes is well controlled and that the glucose level is normalized (or almost) and stable before requesting an ^{18}F-FDG study.

Is there a reasonable doubt of neoplasia in respect to the clinical and para-clinical evaluation?

The prescription of an oncology PET study should ideally be limited to patients with proven or strongly suspected neoplasia. A clear clinical question should be included in the request form for the exam. It is the responsibility of the requesting physician to be as clear as possible.

What is the location of the neoplasia?

The degree of metabolism of a tumor must be put in relationship with the basal metabolism of the organ in which the tumor is sought (Figures 2 and 3). In some cases, this can cause interpretation problems and can limit the sensitivity of the examination. The bladder comes in at the first place of hypermetabolic organs due to the physiological urinary excretion. Fortunately, it is easy to significantly decrease the physiological activity in urinary bladder by diluting its activity through the i.v. administration of furosemide. This

protocol allows therefore to image high grade bladder cancer and to make the assessment of its extension (Figure 10). In contrast, since this is not a procedure carried out on all patients, it is important to specify in the request for examination if there is a suspicion of bladder neoplasia, lesion to the outer wall (implant of a gynecological neoplasia) or at the edge of the bladder (metastatic lymph node). The brain comes in second place of hypermetabolic organs. Unlike the bladder, there is no easy method to decrease brain activity other than by sedation. It is therefore difficult to locate brain metastases in this physiologically very active organ. MRI remains the imaging of choice in the assessment of neoplastic cerebral lesions, but PET is the imaging of choice for monitoring post radiotherapy response.

What is the size of the lesion under evaluation?

The sensitivity and resolution of PET equipment is increasing from year to year. In the optimal conditions, the technology currently available can detect lesions in the vicinity of 4.5 mm. Unfortunately, these perfect conditions are almost impossible to obtain in the human body, and a reasonable estimate of the camera resolution would be at about 6 mm. If the anomaly to be imaged is sought in a mobile organ, the sensitivity decreases as a function of the amplitude of the movement. It is therefore difficult to identify a nodule of 6 mm located at the base of the lung or an infra- centimeter hepatic metastasis juxtaposed to the diaphragmatic dome. To overcome this limit, imaging techniques synchronized with the respiratory rate are now available (respiratory gating).

What is the histological type of the initial tumor and its grade in a context of staging, restaging or when evaluating treatment response?

The higher or more undifferentiated histological the grade is, the more it will accumulate ^{18}F-FDG. Because of their low glucose metabolism, some histological types do not uptake any or will accumulate very little of ^{18}F-FDG so that the role of PET with FDG is limited for these types of tumors: well differentiated prostate cancer, some hypernephroma, small lymphocytic lymphoma (chronic lymphoid leukemia), marginal zone lymphoma, lymphoplasmocytary lymphoma (Waldenstrom), leukemia, well differentiated hepatocellular carcinoma, minimally invasive lung carcinoma (bronchiolo-alveolar), any tumors with high mucin component, low grade neuroendocrine tumor, low grade sarcomas (particularly liposarcoma), teratoma, and some well differentiated breast cancer (particularly the lobular carcinoma).

How much time should we wait between a PET study and the last surgery, radiotherapy or chemotherapy?

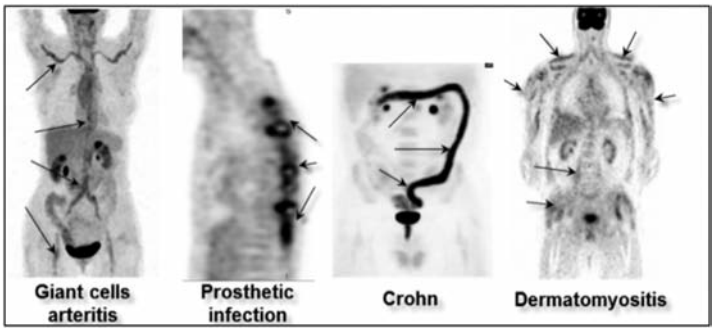

Figure 6:
PET FDG is not only useful in oncology. It can be used for the diagnosis and monitoring of giant cell arteritis, the search for infectious foyers (ex: infection of orthopaedic materials), the diagnosis of myositis/dermatomyositis and even in the assessment of inflammatory intestinal diseases.

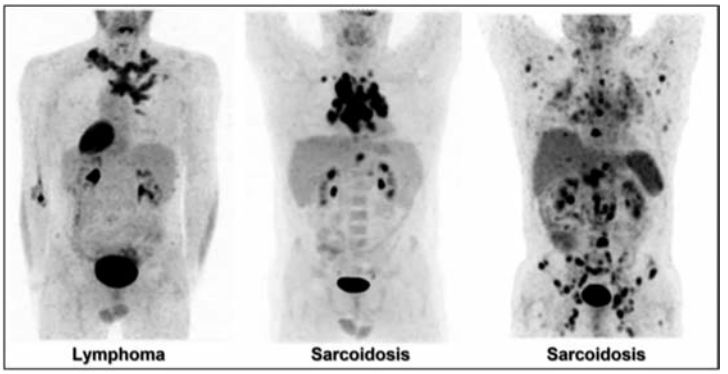

Figure 7:
Active chronic inflammatory granulomatosis conditions, like sarcoidosis, can resemble a lymphoma (center), or even a plurimetastatic disease (right). Some criteria, including the symmetric hilum distribution, the disproportion between the size of lymph nodes and their activity, the presence of lymph nodes and splenic calcifications, are elements in favor of a granulomatous disease. In cases where presentation is more atypical (image on the right), only a biopsy can differentiate between the two entities.

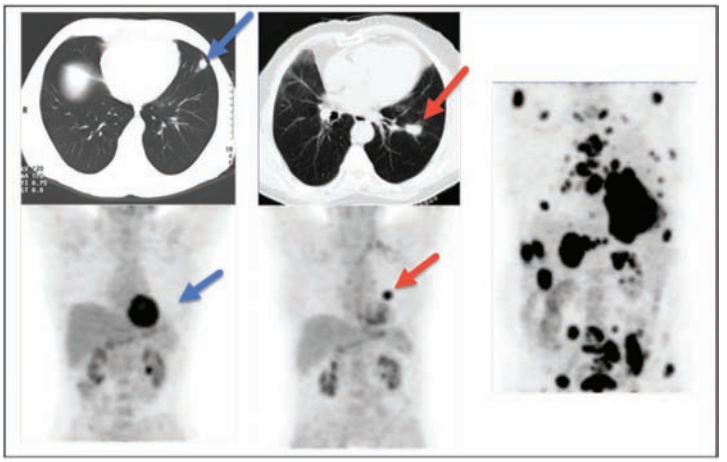

Figure 8:
Evaluation of an undetermined lung nodule. Left Images (CT and PET): Lung nodule to the lingula presenting no significant metabolic activity, compatible with a benign/inflammatory nodule (blue arrows). Center Images (CT and PET): Lung Nodule near the left hilum presenting very significant metabolic activity that is compatible with primary pulmonary malignancy (red arrows). Right Image (PET alone): Plurimetastatic disease (bone, lymph nodes, adrenal glands) from the left lung.

Table 2:

Brain:
- Relapse versus radionecrosis of high-grade gliomas post-radiotherapy
- Primary brain tumor versus metastasis: primary site search

Head and neck:
- Search for a primary site explaining metastatic cervical adenopathy
- Initial staging in suspected advanced stage
- Residual disease assessment post-treatment

Thyroid:
- Thyroid cancer when thyroglobulin level is elevated and radioiodine scan is negative
- Staging and restaging of poorly differentiated thyroid cancer, Hurthle carcinomas, or medullary thyroid carcinomas

Lungs:
- Classification of an undetermined lung nodule
- Pre-operative staging assessment
- Radiotherapy planning in case of significant lung atelectasis
- Relapse versus scar tissue formation post-surgery or post-radiation
- Lower sensitivity for the bronchiolar-alveolar adenocarcinomas

Breast:
- Initial staging and follow-up of locally advanced or metastatic cancer when conventional imaging studies are equivocal or suspicious
- More accurate in triple negative cancers or HER-2 overexpression
- Less sensitive if lobular or well differentiated (hormonosensitive breast cancer)

Oesophagus:
- Initial staging to assess respectability
- Restaging after an induction chemotherapy and/or radiation
- Response to treatment
- Radiotherapy planning

Stomach:
- Useless in the detection of a primary
- Only useful in metastatic assessment

Liver:
- Differentiate between benign or malignant lesions when conventional studies are equivocal or suspicious
- Search for liver metastases
- Cholangiocarcinoma (other than tubular or mucinous)
- Less useful for the well differentiated hepatocellular carcinoma

Pancreas:
- Pre-operative metastatic assessment
- Less useful in the characterization of a mass

Colorectal:
- Local Recurrence versus scar tissue
- Unexplained markers elevation (CEA) in post-therapy context
- Pre-surgical evaluation of a single liver lesion
- Pre-operative adenopathy assessment and search for metastases
- Treatment response
- Less sensitive in the presence of significant mucinous component

Melanoma:
- Search for metastases (Breslow > 1.5 mm), Stages II and III
- Restaging in patients with recurrent disease following therapy
- Less useful in Stage I, because the metastatic risk is < 5 %

- Hodgkin and non-Hodgkin lymphoma:
- Routine pre-treatment staging
- Measure treatment response, chemotherapy and radiotherapy
- Evaluation of relapse
- Restaging before bone marrow graft
- Guide biopsy to the most accessible site

Gynaecologic (cervix):
- Preoperative staging assessment
- Detection of residual disease after treatment
- Restaging at relapse
- Could be of interest for radiotherapy planning

Testicular:
- Search for metastases
- Chemotherapy / Radiotherapy response evaluation
- Teratoma content may cause false positive and false negative studies
- Residual mass assessment/surveillance

Bladder (with iv Lasix, voided bladder):
- Preoperative staging
- Search for metastases in the context of relapse
- Treatment response evaluation

Prostate:
- Should not be used if well differentiated histology and Gleason < 8
- Staging if histologically undifferentiated

Sarcoma:
- More sensitive in high grade sarcomas
- Low grade tumors are frequently false negative

Especially for the evaluation of a local recurrence or that of a treatment response, it is recommended to wait four weeks between the PET study and surgery or chemotherapy, or to wait three months after the last radiation treatment, since the local residual inflammation could cause false positive results. If performed too soon post-treatment, the evaluation may be associated, depending on the case, to a higher rate of false positives or false negatives. It is also important to mention that if the patient is under hormonal therapy, this medication can also affect PET results, same as chemotherapy.

Is there an infection near the site under evaluation? Is the patient known for a non-neoplastic disease that naturally uptakes ^{18}F-FDG?

FDG PET does not provide a way to differentiate between a neoplastic lesion and an active infectious or inflammatory process (Figure 6), since the two latter will avidly capture the ^{18}F-FDG. It is therefore difficult, for example, to differentiate active tuberculosis foyer from a primary pulmonary malignancy or an abdominal abscess of a colonic neoplasia from a lymphoma. Some benign pathologies, like sarcoidosis, active Wegener, tuberculosis, uterine fibroid, thyroiditis, stomach ulcers, acute or chronic cholecystitis and many others may capture FDG. Without biopsy of the lymph node, it is often difficult to differentiate by PET a sarcoidosis from a metastasis or a lymphoma (Figure 7), a uterine fibroid tumor from a sarcoma or yet, the histiocytosis from a multifocal bone metastasis.

Figure 9:
FDG PET performed while taking metformin. Metformin modulates a highly intense FDG accumulation in the bowel (blue arrows) which makes it impossible to detect bowel lesions. Metformin should be stopped at least two days before FDG PET.

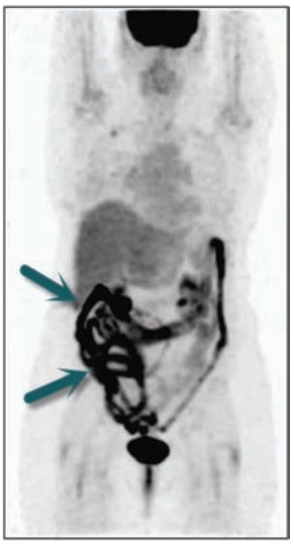

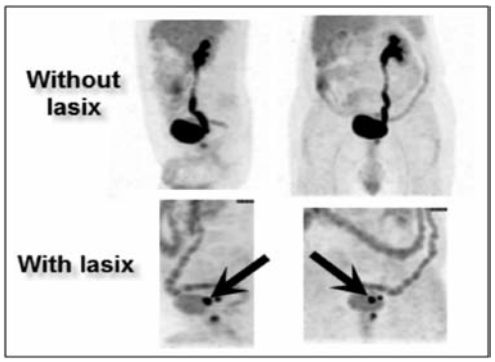

Figure 10:
In the physiologically hypermetabolic organs, some maneuvers may be attempted in order to decrease the basal metabolism and to allow visualization of the tumor. Bladder cancer is the typical example of how the use of a diuretic helps the bladder to drain quickly so that the tumor can be easily set apart (black arrows).

In other words, FDG may accumulate in places with active inflammation, be it acute, chronic, infectious or granulomatous. The distribution of the radiotracer and the appearance of lesions can sometimes allow the nuclear medicine specialist to distinguish between an infection, an inflammatory process or a neoplastic lesion, but it is important to remember that these conditions represent the most frequent cause of false-positive results.

FDG PET is now the oncology standard for several types of cancers. This very powerful diagnostic tool is only in its early stages in Canada and will be called upon even more in the coming years. Even if FDG is an excellent radiotracer for tumors and metastases localization, some cancers cannot be easily assessed with this radiotracer. Consequently, there is a need for new clinical tracers to increase the diagnostic accuracy of PET for cancers where FDG is less efficient. Sodium fluoride is one of the new tracers in clinic which allow earlier detection of the bone metastases (Figure 11). ^{18}F-MFES, an oestrogen derivative under clinical trial in BC and Quebec, is one of the most promising tracers for the detection and staging of hormonosensitive breast cancer (Figure 12).

Since there are multiple factors to consider in a FDG PET study, it is crucial to provide maximal clinical information to the nuclear medicine specialist who will be interpreting the imaging results (pathology reports, summary of surgical procedures, radiology results, blood biochemistry) in order to give a more precise answer to the clinical question. And, for more complex cases, a discussion with the nuclear medicine specialist may be relevant before prescribing the exam. ■

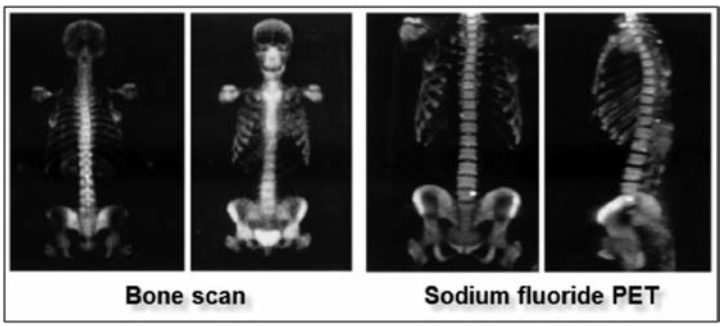

Figure 11:
The future of the PET lays within the development of new radiotracers enabling sensitivity increase of already existing exams and/or newer indications. The development of sodium fluoride PET (NaF PET) as a replacement for the conventional bone scan is an example. This study is carried out 30 to 45 minutes after the injection of the radiotracer and the acquisition of the images only lasts for 35 minutes (compared to a waiting time of 4 hours and 40 minutes imaging, on average, for a regular bone scan). With NaF PET, which is more sensitive and faster, it is possible to locate metastases as small as 5 mm.

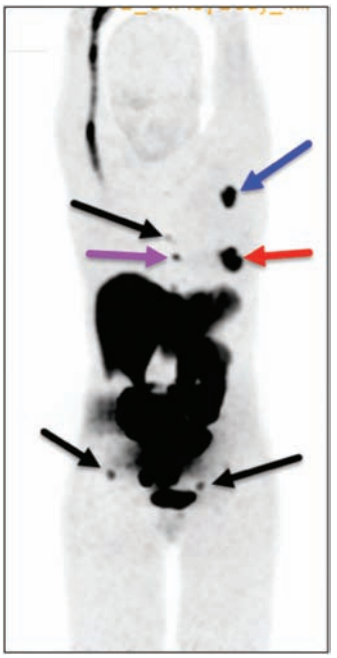

Figure 12 :
PET performed with ^{18}F-MFES, an oestrogen derivative highly sensitive to detect hormonosensitive breast cancer and metastasis. Clinical trials, funded by the Canadian Breast Cancer Foundation, are underway in Quebec and in the initial phase in BC. Red arrow: Primary breast cancer. Blue arrow: axillary metastasis. Purple arrow: internal mammary metastatic lymph node. Black arrows: Bone metastasis.

Dr. Rodrigo Jaimovich, M.D
Past-President of ALASBIMN
Professor, Nuclear Medicine
at Clinica las Condes S.A
Chili University, Chili

APORTE DEL SPECT/CT EN TÉCNICA DEL GANGLIO CENTINELA PARA CÁNCER DE MAMA



La adecuada evaluación del compromiso ganglionar axilar en cáncer de mama es de tremenda importancia tanto para el pronóstico del paciente así como para la toma de decisiones acerca de la terapia. En algunos casos puede implicar una mayor acción quirúrgica que incluya el vaciamiento ganglionar de la axila, o bien aumentar los campos a irradiar durante la radioterapia. Además muchas veces el status ganglionar define si se debe agregar quimioterapia como terapia adyuvante.

La técnica del ganglio centinela se ha transformado en la mejor forma de evaluar el compromiso axilar en cáncer de mama ya que identifica al primer ganglio tributario del drenaje linfático proveniente del tumor. Al identificar ese ganglio se puede resecar y analizar en forma exhaustiva con técnicas histoquímicas. Se ha demostrado que la capacidad predictora del status axilar a partir del ganglio centinela es muy buena, sobre el 95%, por lo que un estudio de ganglio centinela negativo predice con un alto nivel de certeza que el resto de los ganglios axilares no tienen diseminación tumoral.

Para identificar el ganglio centinela se utilizan dos técnicas que se basan en el mismo principio, una radioisotópica y otra con colorante. En ambas se inyecta una dosis de radiofármaco o colorante en la mama, generalmente en región periareolar en el cuadrante del tumor, de forma intradérmica. Posteriormente se espera a que el trazador (radioactivo o colorante) migre a través del sistema linfático hasta encontrar un ganglio en su camino donde se acumula progresivamente. En el caso de la técnica con radioisótopos se realiza una imagen para demostrar la acumulación en el o los ganglios centinelas, se marca su ubicación para posteriormente ir a la resección quirúrgica. En pabellón se utiliza un detector portátil de radiación para ayudar a encontrar los ganglios radioactivos. En muchos centros se utilizan ambas técnicas en forma complementaria, realizando la marcación radioisotópica pre-operatoria, y en pabellón se agrega además el colorante. La combinación de ambas técnicas es la que mejores resultados ha reportado en cuanto a la correcta identificación del ganglio centinela.

Si bien la técnica radioisotópica ha demostrado excelentes resultados, existen algunas variaciones respecto a la forma original de adquirir las imágenes. En otros tumores donde también se identifica el ganglio centinela como el melanoma maligno, se ha planteado combinar las imágenes planares con una adquisición tomográfica (SPECT) a las cuales se les agrega una imagen anatómica (CT) que sirve tanto para mejorar la calidad de imagen como para dar un correlato espacial a la imagen de medicina nuclear. Esto es de particular interés en los melanomas de cabeza y cuello debido a la complejidad de las estructuras y espacios cervicales, donde se ha demostrado la superioridad de la técnica híbrida SPECT/CT sobre la planar tradicional en la detección del ganglio centinela.

La experiencia de la técnica de ganglio centinela con SPECT/CT en cáncer de mama es variada, reportándose algunas situaciones donde se obtienen beneficios con la técnica de imágenes híbridas. La indicación del SPECT/CT más común es la no visualización del ganglio centinela en las

imágenes planares. Esto puede ocurrir por diversas razones, siendo la principal la superposición de la radioactividad del sitio de inyección con la ubicación del ganglio centinela, quedando este último oculto. Otra causa es que la radioactividad acumulada en el ganglio centinela sea muy baja, impidiendo que sea visualizada en las imágenes planares. Las imágenes tomográficas con técnica SPECT/CT permiten identificar los sitios de radioactividad y diferenciarlos del sitio de inyección. Además la reconstrucción de las imágenes con esta técnica entrega una mejor resolución, superior a la planar, por lo que se logran identificar ganglios muy pequeños y/o con baja captación. Esto ha permitido disminuir la cantidad de estudios donde no se lograba identificar los ganglios centinela mediante las imágenes pre-operatorias.

Otra condición donde la técnica híbrida ha demostrado superioridad es la correcta identificación de sitios de drenaje atípico. Existe un porcentaje de pacientes donde el drenaje linfático no se dirige a la región axilar ipsilateral, siendo posible un drenaje hacia la cadena mamaria interna o a región supraclavicular. Este tipo de drenaje puede darse en forma exclusiva o concurrente con el drenaje hacia axila. La correcta identificación del territorio de drenaje permite a los cirujanos tomar decisiones acerca de la potencial resección de esos ganglios con drenaje atípico. Además, se ha postulado que la presencia de drenajes atípicos cuando no se identifica drenaje axilar puede reflejar una mayor probabilidad de que esos ganglios estén comprometidos. La explicación de este último fenómeno sería que, al infiltrarse los ganglios con metástasis tumorales, se bloquea su capacidad de captar el trazador, por lo que se "salta" a la siguiente estación ganglionar.

Se ha descrito una dificultad en la marcación del ganglio centinela en pacientes obesas, existiendo una correlación directa entre el valor creciente del índice de masa corporal y la menor tasa de detección de ganglios centinelas mediante la técnica planar tradicional. Esto se debe a la mayor atenuación que ocurre por la mayor profundidad de los ganglios. Cuando se realiza la técnica de SPECT/CT con la consiguiente corrección de atenuación, la tasa de detección de los ganglios aumenta significativamente.

Si bien no hay reportes de disminución del tiempo operatorio en pacientes que se realizan la técnica de ganglio centinela en cáncer de mama con método SPECT/CT versus planar, existe la referencia de esta disminución en casos de melanoma maligno. La información entregada por el SPECT/CT sí es apreciada por los cirujanos en términos de contar con la mayor cantidad de referencias para la exitosa localización del ganglio centinela. Lo primero es el número correcto de ganglios que muestran captación,

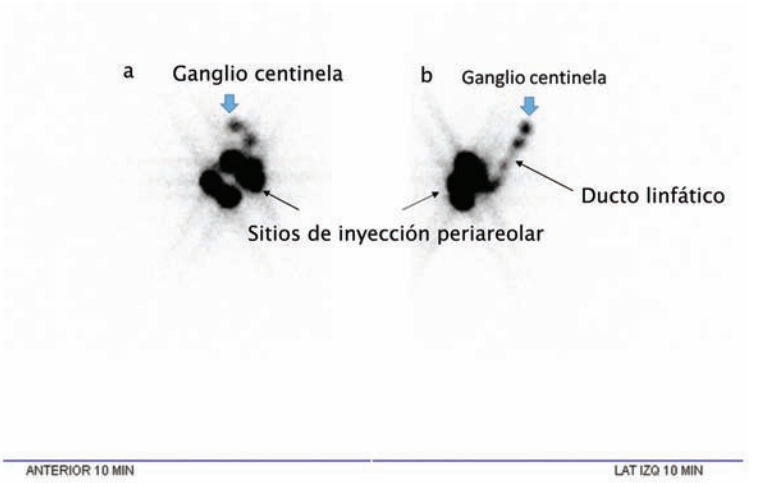

Figura 1
Proyección anterior (a) y lateral (b) de mama izquierda con sitios de inyección periareolar (4), ducto linfático y ganglio centinela.

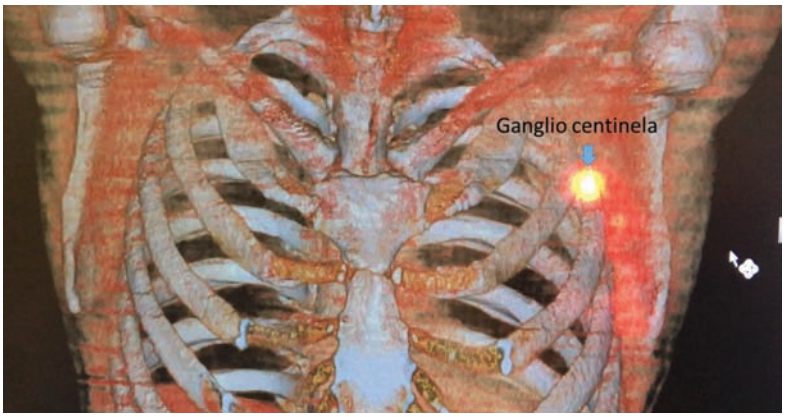

Figura 2
Misma paciente con adquisición SPECT/CT demostrando la ubicación del ganglio centinela con sus relaciones anatómicas cercanas.

diferenciarlos correctamente de captación en ductos linfáticos. Además el CT entrega una adecuada posición del ganglio, en cuanto a profundidad, relación con otras estructuras (músculos, vasos, pared costal) y eventuales ubicaciones atípicas como ya se mencionó.

La técnica del ganglio centinela se ha instalado como parte de la mejor forma del manejo de la cirugía del cáncer de mama. La correcta identificación de este ganglio permite entregar una información relevante al equipo tratante ya que permite definir el pronóstico de la paciente y su eventual tratamiento. Esta técnica se ha visto mejorada con la incorporación de las imágenes híbridas con el SPECT/CT, especialmente relevante en casos donde la técnica planar no logra detectar adecuadamente el ganglio centinela. ■

Kalevi Kairemo

Department of Nuclear Medicine and Molecular Radiotherapy, Docrates Cancer Center, Helsinki, Finland

THERAGNOSTICS: Lu-177-PSMA treatment for metastatic prostate cancer – case examples



Prostate specific membrane antigen (PSMA) is a membrane glycoprotein with enzymatic activity (as explained in vol.1 no.2. by Jean-Luc Urbain). It is highly expressed in high-risk prostate cancer and therefore PSMA could be a basis for theragnostics. ^{177}Lu-PSMA radioligand therapy is mainly used for patients with end-stage prostate cancer, but it can be used earlier. I describe here three patients: one patient with a multiple recurrences and one with extensive metastastic disease during the first visit, and one patient where it was used as first-line treatmen. All these patients demonstrated a major response with ^{177}Lu-PSMA radioligand therapy, i.e. complete response by imaging and substantial reduction of PSA. ^{177}Lu-PSMA radioligand therapy gave only mild adverse effects.

Our first patient had hypertension and diabetes for years. Primarily PSA increased from 4.6 to 17 ng/ml within 6 months. Diagnosis was done based on second round of biopsies 16 years ago when GS 6 (3+3) prostate adenocarcinoma was found in both lobes. Hormonal therapy was started with leuprorelin and bicalutamide. Prostatectomy was performed 6 months later. Tumor was very large and it was infiltrating also to seminal vesicles, consistent with staging pT3b. The full case history including serum PSA behavior is shown schematically in Fig.1, but briefly the case history is as follows.

One year later he got external beam radiation therapy to prostate fossa up to 70 Gy, bicalutamide and casodex were used for 3 years, until goserelin was started for 2 years. Bicalutamide was re-started one year later due to PSA increase (up to 4.1 ng/ml). Degarelix was introduced 2 years later for one year. Simultaneously, choline-PET-positive para-iliac and paracaval lymph nodes were irradiated up to 70/2 Gy. However, in PSA continued to increase up to 24 ng/ml and 7 cycles of docetaxel were given with partial response. Four months later, skeletal metastases were found in MRI, and palliative radiotherapy to lumbosarcal region was given. Histrelin acetate device was implanted for castration. Abiraterone and denosumab were started, but they were stopped due to the pain in muscles and joints in four months. The castration implant removed and abiraterone started again for 4 months. Denosumab was also started and continued for more than a year.

Degarelix was restarted, but it was changed to leuprorelin due to local and systemic reaction. He also got radiation therapy to choline positive upper retroperitoneal and mediastinal lymph nodes. Enzalutamide was also started but it had to be stopped in one month due to epileptic seizure. Six month later, dexamethasone combined with cyclophosphamide started to improve immunogenic response, but it had to be stopped due to the diarrhea, swelling and infection. Abiraterone started again, but four months later PSA was 33 ng/ml. On the same day in Ga-68-PSMA-PET-CT at

demonstrated active uptakes in very small lymph nodes on the left side of obturator region, in upper level in para-aortal and in para-caval lymph nodes and in retrocrural region, in the middle of left mediastinum and in supraclavicular region as well. The total volume of the disease estimated to be 20 cm^3.

^{177}Lu-PSMA-617 treatments were given in July, August and October 2016 using 6 week intervals. PSA nadir 0.0 ng/ml was achieved on in March 2017. Complete response was seen in ^{68}Ga-PSMA-11 PET-CT in March 2017 (Fig. 1, lower panel right). The patient is still alive and followed without any specific cancer therapy until January 2018. However, he felt down and broke his femur which was operated. The man is now 82 years.

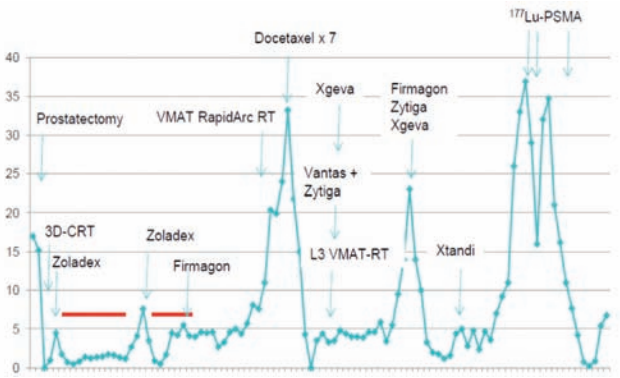

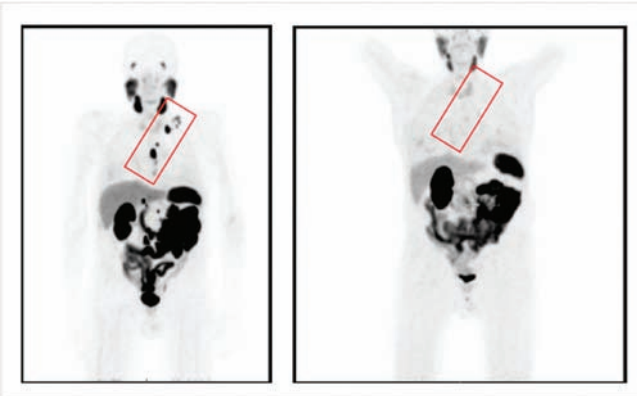

The second patient described here had primarily nocturia, pollacisuria and weak urinary flow resulting in more specific clinical studies four years ago. Initial S-PSA was 216 ng/ml. The biopsies revealed a Gleason Score (GS) 9 (5+4) adenocarcinoma with perineural invasion and extracapsular growth. Clinically the patient was T4, but there were no skeletal metastases in bone scintigraphy. Total androgen blockade (TAB) with leuprorelin plus bicalutamide was started for locally advanced prostate cancer with bilateral hydronephrosis and serum creatinine value 150. After bilateral pyelostomy operations, the patient could also urinate normally twice a day. TAB continued until March 2017. Bone scintigraphy already demostrated a superscan, and CT showed bone metastases with serum PSA value 135 ng/ml, without visceral metastases. At the end of March bicalutamide was stopped and abiraterone was started. Abiraterone was again stopped when ^{177}Lutetium-PSMA started. Patient refused to take any chemotherapy.

Ga-68-PSMA-PET/CT was performed in April 2017. It revealed an active and aggressive prostate malignancy in the left seminal vesicle region and extensive wide-spread strongly PSMA-positive skeletal disease. The Soloway classification was 3+/3, because extremely high uptakes in lower thoracic spine and sacrum and signs of bone marrow expansion existed. The SUVmax-values were higher than 27, while values higher than 3 are considered pathologic. The serum PSA value was 375 ng/ml.

^{177}Lu-PSMA therapy started in May 2017. It caused tiredness and he had also swelling in foots and ankles, but surgical stockings helped that. The patient had also severe depression and anguish. Following 4th treatment in September 2017 man had nausea and emesis. After 6th treatment he had no nausea and general feeling was also good. This man is now 70 years old.

An interim control Ga-68-PSMA-11-PET/CT was performed at Docrates Cancer Center in late October 2017. The serum value was then 9.4 ng/ml. Fig. 2 demonstrates the Ga-68-PSMA-11-PET/CT-studies performed in late April and late October 2017, i.e. before therapies and 4 weeks after the 4th cycle. In the base line study an extensive skeletal disease can be seen in the MIP-image and also in pelvic fusion image (PET on CT). Normal organs, i.e. salivary and lacrimal glands, liver, spleen hardly visualize in the MIP-image. Additionally, an uptake is seen in the large prostate and in the left seminal vesicle. The interim control PET MIP-image reveals normal organs such as salivary and lacrimal glands, liver, spleen, kidneys and urinary bladder. Very little activity can be observed in the thoracic vertebra (Th 3). In interim control pelvic fusion image (PET on CT) there is no activity in the large prostate nor in the left seminal vesicle.

In control Ga-68-PSMA-PET/CT on in mid-January 2018 at Docrates Cancer Center and 6 weeks after the 6th cycle the active and aggressive prostate malignancy in the left seminal vesicle region had totally disappeared. Similarly, an extensive wide-spread strongly PSMA-positive skeletal disease, original classification probably 3+/3, had responded in all regions. There was only one subtle uptake on the left in Th3 which could be seen as in Fig.2, but the activity could already be considered normal, because the SUVmax value was only 3.8. This was considered as a dramatic response. PSA decreased from 375 ng/ml downto 4.2 ng/ml during the follow-up ^{177}Lu-PSMA therapy. This is shown in Fig. 2.

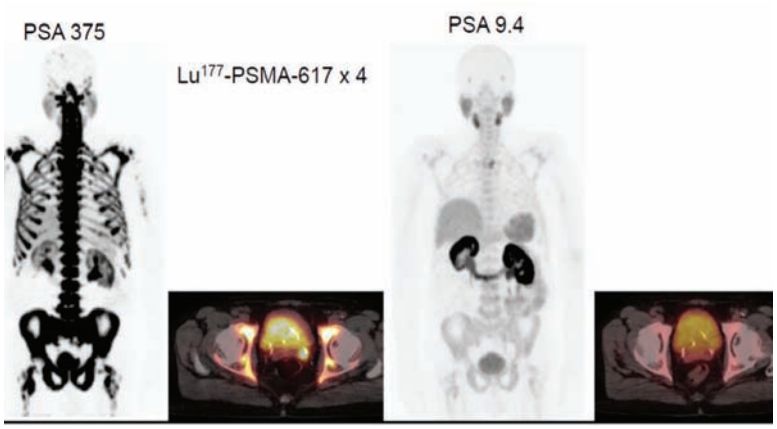

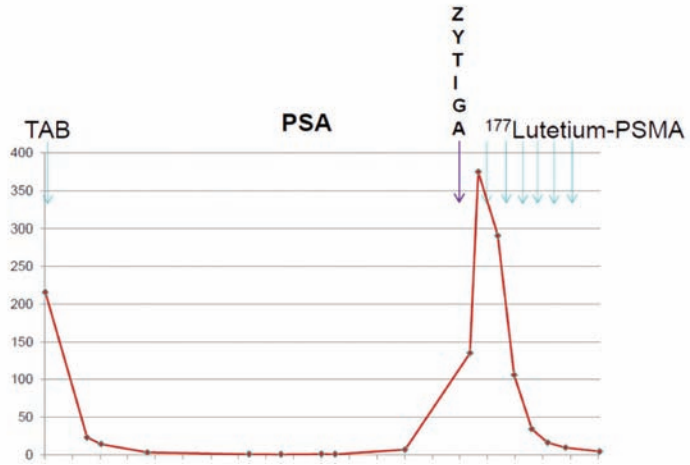

Case 3. Aggressive GS 9 /4+5) prostate cancer in biopsies was found with PSA 28. Man was 59 years. Based on staging 4 by CT and bone scan, man was told that the given therapies according to National and International guidelines are not curative. Therefore he looked second opinion from DCC. Endorectal multiparametric prostate MRI together with NaF- and ^{68}Ga-PSMA-PET-CT confirmed the staging to be T4N1M1. A 9x23 mm lymph node chain and a separate 7 mm node in the mesorectum on the left side, a 3 and a 5 mm suspicious node on the right side, and more cranially in the mesorectum at least two 7 mm nodes, a 9 mm obturator and a 9 mm external iliac node on the left and a 7 mm external iliac node, on the right M1a: 10 mm right common iliac node. In ^{68}Ga-PSMA-PET-CT active and aggressive prostate malignancy was observed mainly in the left lobe with local extension and extensive lymph node disease in the pelvic spaces, the lymph node disease located predominantly on the left with a total volume of 75 cm^3 and it was very active with SUVmax ad 47.

There was lymph node disease in obturator, perirectal, parailiac (ext/int), common iliac, presacral nodes. Wide-spread skeletal disease with low volume (25 cm^3), classification 1/3, but with high uptakes e.g. in lower spine (SUVmax >30); solitary metastases in the skull, spine, thorax and left proximal femur. Since the disease was shown to be aggressive, man was young and very healthy, and the cancer cells appeared to be avid for PSMA we decided to start the therapy using Lutetium^{177}-PSMA together with more traditional hormone treatment. Patient decided to stop smoking also.

In the first early response evaluation PSA went down 37.8 to 0.16 ng/ml and the response was confirmed also by ^{68}Ga-PSMA-PET-CT scanning, demonstrating practically complete response by imaging. Earlier active and aggressive prostate malignancy was not anymore active (SUVmax < 2.7). The local extension and extensive and active lymph node disease in the pelvic and retroperitoneal spaces (obturator, perirectal, parailiac (ext/int), common iliac, presacral nodes) had completely vanished. Similarly, the wide-spread skeletal disease (skull, spine, thorax and left proximal femur) had fully disappeared. The PSMA-positive disease (skeletal 25 cm^3 + lymph nodes 75 cm3) demonstrated a visual metabolic complete response. Quantitative "PERCIST"-response turned out to be -93%.

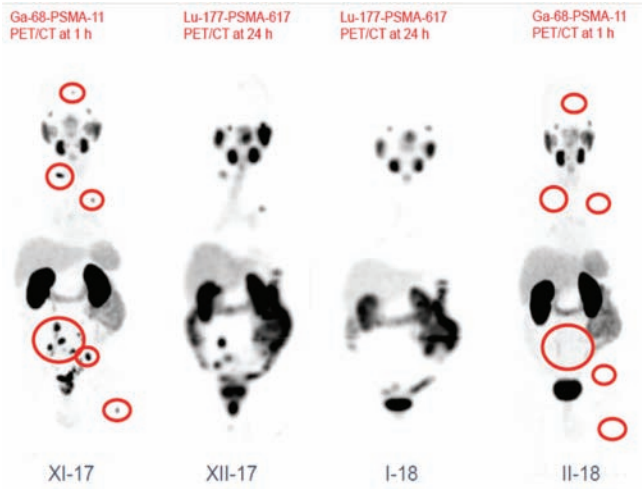

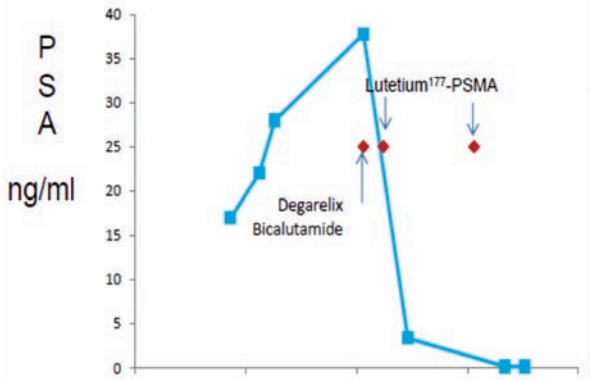

CANM ACMN

The Canadian Association of Nuclear Medicine

Association canadienne de médecine nucléaire

CANM GUIDELINES FOR VENTILATION/PERFUSION (V/P SPECT) IN PULMONARY EMBOLISM

Executive Summary

Document prepared by
Drs. Michel Leblanc, Michel Tessier, Glenn Ollenberger, Christopher O'Brien

November 2018

1. Diagnostic approach for PE.
Generally, predictive models based on clinical data for PE are poor.

D-dimer has high NPV but low specificity for PE, and is not needed if the pretest probability for PE is other than low.

V/P SPECT has at least the same or better accuracy for PE as CTPA, but much lower radiation dose especially regarding breast exposure. Also, there have been little or no reported adverse reactions.

2. Methodology
V/P SPECT should be used instead of planar acquisition when available. Multidetector gamma-cameras with large FOV are preferred for V/P SPECT. A one-day ventilation and perfusion protocol where the ventilation precedes the perfusion is the norm.

For ventilation, ^{99m}Tc-Technegas is the best radio-aerosol, particularly in patients with COPD. Liquid aerosols produced in nebulizers such as ^{99m}Tc-DTPA are inferior for SPECT and should not be used unless Technegas is not available.

Lung perfusion is performed using ^{99m}Tc-macroaggregated albumin (MAA). Suggested administered doses and acquisition parameters are presented in **table 1** of attached document. Appropriate iterative reconstruction and display of transverse, sagittal and coronal projections are essential for interpretation.

3. Interpretation criteria and reporting
Interpretation in probabilistic terms is not appropriate and must be avoided. Accordingly, all exams should be interpreted as either "PE present" or "PE absent" or other similar clear affirmative terms.

Affirmative diagnosis of PE requires the presence of vascular type mismatches. **PE is considered excluded** if perfusion is normal, if there are only matched defects, non-vascular type mismatches or reverse mismatches. See document for explanations.

Findings other than PE may be clinically pertinent, especially if symptoms include dyspnea or desaturation.

All PEs should have a final control 3 months after diagnosis to assess final reperfusion and to benefit from the availability of a baseline exam in case of recurrent symptoms.

4. Other considerations
In the **pediatric population and during pregnancy**, one should consider V/P SPECT as the first investigation for suspected PE due to better sensitivity, lower radiation, and no adverse reactions.

As ventilation co-morbidities are unlikely, a perfusion-only study might suffice, with an optional ventilation study the next day if needed. However, V/P SPECT should be used in pregnant women with co-morbidities or a history of smoking.

Due to a higher sensitivity and no adverse reactions, V/P SPECT should be the first investigation for the assessment of **Chronic PE**.

Although we do not recommend performing **SPECT-CT** on a regular basis, it could be appropriate in more challenging and selected cases.

CANM Endorsement of the 2009 EANM Guidelines for Ventilation / Perfusion Scintigraphy

1) Diagnostic approach to pulmonary embolism (PE)

Key Points:

1. **Predictive models for PE are generally inaccurate**
2. **D-dimer has high sensitivity but low specificity for PE**
3. **Negative D-dimer has a high NPV**
4. **High quantitative value of D-Dimer increases likelihood for PE**
5. **D-dimer is not needed if pretest probability for PE other than low**
6. **V/P SPECT has at least the same or better accuracy for PE as MDCT**
7. **Availability is the main determinant of use for MDCT vs V/P SPECT**
8. **Fetal dose is roughly equivalent for both V/P SPECT and MD-CTPA**
9. **Breast dose is much higher with MD-CTPA as compared to V/P SPECT**
10. **V/P SPECT carries less risk of allergic reaction associated with contrast agent injection**
11. **99% of patients referred for V/P can undergo the exam.**

Referral criteria and assessment of clinical probability

For the diagnosis of PE the patient's clinical factors are non-specific. The clinical probability of PE can be accomplished empirically or by means of a prediction rule. Wells model is most frequently used. PISA model may be a more precise predictor of PE. Combining clinical probability with objective testing for PE can rule in or out PE. The measurement of D-dimer is widely used in the investigative work-up of patients with suspected venous thromboembolism. D-dimer features a low specificity (40%). Accordingly, a negative quantitative D-dimer test has a high negative predictive value for venous thromboembolism. High quantitative value of D-Dimer increases likelihood for PE

CANM endorses Fig. 1 and 2 - **Clinical algorithms for investigation of patients with suspected PE** as published in *Eur J Nucl Med Mol Imaging* (2009) 36:1528–1538.

Imaging studies in PE

The diagnosis of PE relies upon imaging tests, notably V/P scan and MDCT. In many clinical studies, including recent ones, comparisons between V/P scan and MDCT have been based upon obsolete scintigraphic techniques and interpretation criteria. The lack of a satisfactory gold standard for the diagnosis of PE poses difficulties for the assessment of sensitivity, specificity and accuracy of all diagnostic methods for PE. V/P SPECT has at least the same or equal accuracy for PE as MDCT. Additional diagnoses found on V/P SPECT include COPD, left heart failure and pneumonia. MDCT provides valuable information about diagnoses other than PE, such as aortic aneurysm, tumour, pleural effusion and pneumonia. A high number of patients are ineligible for MDCT due to kidney failure, allergy, ventilator support, recent MI and critical illness. 99% of patients referred for V/P can undergo the exam. CTPA is more readily available on a 24/7 basis and thus may be used more often.

Radiation Doses

The effective radiation dose from V/P SPECT is 1.2–2 mSv. The absorbed dose to the female breast is estimated as 0.8 mGy. During the first trimester, the estimated dose for perfusion study (50 MBq) gives a fetal absorbed dose of 0.1–0.2 mGy [47].

For MDCT during the first trimester the absorbed fetal dose was estimated as 0.24–0.66 mGy and significantly higher later during gestation. Recent studies have shown that MDCT is often technically suboptimal during pregnancy. The rate of nondiagnostic MDCT studies was 27.5% during pregnancy, versus 7.5% in nonpregnant women.

Based upon data from ICRP reports, the effective dose for V/P SPECT with the recommended protocol is about 35–40% of the dose from MDCT. The dose to the female breast for V/P SPECT is only 4% of the dose from MDCT. During the first trimester of pregnancy the fetal dose from MDCT is greater than or equivalent to that of V/P SCAN. The advantage of V/P SPECT increases after the first trimester.

Follow-up

V/P SPECT is ideally suited for use in the follow-up of PE because small and large emboli are recognized so that regression or progression of thrombotic disease can be studied in detail. Furthermore, the low radiation exposure allows repeated studies. It can be applied **in all patients**. Using the same method for diagnosis and for follow-up has great advantages. Perfusion-only scintigraphy may be chosen for control during the initial phase of treatment

CANM endorses Fig. 3 - **Algorithms for diagnostic imaging for acute PE suspected** as published in *Eur J Nucl Med Mol Imaging* (2009) 36:1528–1538.

2) Methodology

Introduction

Planar ventilation/perfusion technique with probabilistic interpretation suffered disrepute since the PIOPED I study showed that 65% of scans were nondiagnostic for PE. Consequently, it has become an inferior technique for most clinicians and should be replaced by more advanced nuclear medicine imaging using SPECT acquisition whenever available. The following recommendations regarding the choice of radiopharmaceuticals and imaging strategies for V/P studies are based on the 2009 EANM guidelines, updated with the more recent literature.

Radiopharmaceuticals

Ventilation

^{81m}Kr (krypton) is currently the only gas appropriate for V/P SPECT. However, because of high costs and limited distribution, it is not readily available in Canada. The best widely available agent for ventilation is ^{99m}Tc-Technegas, an aerosol of carbon nanoparticles (5-200 nm) generated in a high temperature furnace (Technegas Generator, Cyclomedica). Because of the very small particle size, this agent is distributed in the lungs almost like a gas and deposited in alveoli by diffusion, where they remain stable, thus providing the best possible images for ventilation SPECT. In practice, between 400-900 MBq (1025 mCi) of $^{99m}TcO_4$ in 0.15ml NS is vaporized in a graphite crucible at 2750 °C in an argon atmosphere. The resulting ^{99m}Tc-Technegas is inhaled as soon as possible (<5 minutes) by the patient in a supine position, over the course of 2 to 5 inspirations. Activity over the lungs should be monitored, and administered activity should be around 30-50 MBq (0.8-1.4 mCi).

Liquid aerosols produced in nebulizers, such as ^{99m}Tc-DTPA, are inferior for SPECT, and should not be used unless technegas is not available. Overall, technegas remains the best radio-aerosol, particularly in patients with obstructive lung disease. Another advantage is that only a few breaths are sufficient to achieve an adequate amount of activity in the lungs, reducing time and personnel exposure to radiation.

Perfusion

Lung perfusion is performed using ^{99m}Tc-macroaggregated albumin (MAA). These albumin particles average 10–90 um in size, which allows them to lodge in the pulmonary capillaries and properly define lung perfusion. Normally, about 400,000 particles are injected, but a reduction to between 100,000 and 200,000 is recommended in patients with severe pulmonary hypertension or after a single lung transplantation. A minimum of 60,000 particles is needed to obtain a uniform distribution.

The suspension containing ^{99m}Tc-MAA should be gently shaken immediately before use and then administered by slow i.v. bolus injection over several respiratory cycles while the supine patient breathes at normal tidal volumes. Withdrawal of blood into the syringe must be avoided to prevent aggregation artefacts. The administered dose is typically between 120–240 MBq (3-6 mCi) but actually depends on the count rate of the ventilation agent. The activity ratio between perfusion and ventilation should be at least 4:1. The EANM guidelines recommend doses at the low end of the range to keep radiation exposure low (< 2.5 mSv).

Equipment and imaging protocols

A one-day ventilation and perfusion protocol where the ventilation precedes the perfusion is the norm. Ventilation is essential to maximize specificity and may help recognize alternate pathologies. A perfusion only protocol might be considered during pregnancy (with an optional day-after ventilation study if needed) or in the context of massive PE.

Planar acquisition should not be used anymore, unless SPECT is not feasible for some reason. In this case, six to eight projections are recommended for both ventilation and perfusion. The recommended matrix size is 256x256 in combination with a LEHR collimator, and acquisition time should be long enough to yield 500–1,000 kcounts per view.

Multidetector dual or triple head γ-cameras with large FOV are preferred for V/P SPECT. LEHR parallel collimators with 128 x 128 matrix size represents a good combination, but LEAP collimators with a 64 x 64 matrix are also adequate especially if one aims for lower doses and/or shorter acquisition times. It is important that the patient remains in the

same supine position, carefully maintained between ventilation and perfusion acquisitions. A total acquisition time of 20–30 minutes (excluding dead time) is usually sufficient to complete both the ventilation and the perfusion SPECT scans. Ranges of acceptable doses and acquisition parameters are shown in Table 1 below. Ultimately the doses to be administered should be determined by each institution on the basis of the image quality obtained in a reasonable time, which is influenced by factors such as camera sensitivity, collimator choice, acquisition matrix size, processing parameters and local radiation protection guidelines. The added benefit of SPECT-CT is still debated, but the SPECT part acquisition parameters are similar, if there is a need to acquire CT data in selected cases.

Table 1: Suggested doses and acquisition parameters for V/P SPECT

Parameter	Value range
Administered dose Ventilation	30 - 50 MBq
Administered dose Perfusion	120 - 240 MBq
Collimator and Matrix size	LEHR (128 x 128), LEAP (64 x 64)
# steps / 360°	64 - 128 (32 - 64 / detector)
Step time for Ventilation	10 - 25 seconds
Step time for Perfusion	5 - 15 seconds
P/V activity (count rate) ratio	at least 4:1

Reconstruction and display

Transverse, sagittal and coronal projections are generated using an OSEM (ordered-subset expectation maximization) or equivalent iterative reconstruction algorithm. The number of iterations, subsets and other parameters may vary according to the manufacturer's software used to this end, but overly noisy images should be avoided as they do not promote reproducible interpretations. A 3D post reconstruction filter is usually applied, and the final images can be reviewed in each of the orthogonal planes, preferably on a workstation with dedicated software. Pseudo-planar images can be generated using an angular summing technique and other methods. More advanced data processing can also be performed. Defect contrast on perfusion SPECT can be further enhanced by subtracting the background activity remaining from the preceding ventilation scan. Further, by examining the pixelbased V/P ratio, quotient images can be generated from the SPECT data. These parametric images can facilitate reporting and improve the demonstration of defect location and extent.

3) Interpretation criteria and reporting

- Basic criteria
- Affirmative or negative w/r to PE
- Other possible diagnoses
- Follow-up recommendations

Interpretation

Interpretation in probabilistic terms is not appropriate with VQ SPECT and should be abandoned. All images should be interpreted as either "PE present" or "PE absent" or other similar clear affirmative terms. A small number of "non-diagnostic or equivocal studies" is inevitable for various reasons but should not exceed 5% of the case load.

Affirmative diagnosis of PE requires the presence of vascular type mismatches. Vascular type perfusion defects have the following characteristics: moderate to severe defects, with clear borders, which are pleural based, wider at pleura than centrally, with an orientation compatible with pulmonary vascular anatomy. At the sub-segmental level, the shape is usually triangular.

PE present: PE is diagnosed if there is at least one lobar or segmental vascular type mismatched defect (perfusion defect with preserved ventilation), or two sub-segmental vascular mismatches, regardless of other findings.

PE absent: PE is considered excluded if perfusion is normal, if there are only matched defects (regardless of morphology), non-vascular type mismatches or reverse mismatches (perfusion preserved but ventilation absent).

A frequent cause of non-vascular mismatches is physiologically compressed lung. Typical locations are posterior para-mediastinal lung, costophrenic angles, the top of the great fissures and shallow posterior lung surfaces in cases of gravity dependant atelectasis. Other causes include penetration of ventilation agent in emphysema bullae or cystic space in severe fibrosis.

False positives interpretation may occur mainly in extrinsic vascular compression, pulmonary vein stenosis and rare cases of vasculitis.

The interpretation of an isolated vascular-type defect that is matched on ventilation and congruent with a radiographic opacity of similar size remains controversial because an isolated pulmonary infarct is a possibility (albeit not a frequent one). If symptoms are not acute (more than a few days), partial reperfusion of embolic disease can give atypical perfusion patterns. In difficult cases, consultation with the clinician is suggested.

Other diagnoses

Other findings than PE may be clinically pertinent, especially if symptoms include dyspnea or desaturation.

- Cardiac failure: redistribution of perfusion to superior and anterior portions of the lungs (inversion of the normal gradient) associated with preserved normal ventilation gradient is highly suggestive of early cardiac failure and can be observed earlier than on chest X-ray. This redistribution of perfusion is often lost with more advanced failure and typical X-ray change of edema.

- COPD: The magnitude of changes observed on VQ SPECT correlates with COPD severity, which can be underestimated clinically. Changes are typically more severe on ventilation, which include varying degrees of heterogeneity, ventilation defects and aerosol deposition at various bronchi levels indicating turbulence.

- Reverse mismatch: indicates failure of the physiological pulmonary vasoconstriction in the presence of a ventilation defect. May contribute to hypoxemia because of right-to-left shunt effect. Frequent association with pneumonia and may also be seen in atelectasis, mucous plug or other causes of bronchi obstruction.

Follow up

All PEs should have a final control 3 months after diagnosis to assess final reperfusion and benefit from the availability of a baseline exam in case of recurrent symptoms. Once a diagnosis of PE is made, a follow up exam is necessary to evaluate the degree of reperfusion. This has 2 purposes. First, incomplete reperfusion of a moderate to extensive PE is associated with the development of chronic pulmonary hypertension. Second, if there is a suspicion of new PE on follow up, it may be impossible to distinguish new PE from unresolved prior PE.

If PE is extensive, routine early control 7-10 days after diagnosis is advisable since a substantial part of reperfusion may occur in the first week. If there is early suspicion of new PE, this early control may be invaluable for correct diagnosis in this group.

Interpretation of new defects on control VQ SPECT has some known pitfalls. Sometimes, a partially occluding proximal defect may dissolve in several distal severe defects. Although those defects may seem impressive, they are not new. Also, clots located close to branching arteries may dissolve proximally and part of the clot may be drawn in the adjacent artery.

4) Additional considerations

CHART 1: ACUTE PE

	V/P SPECT	V/P SPECT/ low dose CT
SENS	93-97	93-97
SPEC	91-96	98
NPV	97-99	97-99
Inconclusive	1-3	~1
Nephrotoxicity	none	none
Mortality	none	none
Allergy	none	none

COMMENT: low dose non-contrast CT improves specificity and reduces inconclusive findings in selected patients. SPECT/CT is not recommended as a routine procedure in the diagnosis of PE.

CHART 2: RADIATION EXPOSURE

V/P SPECT	V/P SPECT/ low dose CT	CTPA (4 to 16 slice)	CTPA (64 slice)
~ 2.1 mSv	~ 3.1 mSv	~ 5.4 mSv	~ 20 mSv

COMMENT: exposure from CTPA is difficult to assess as many variables influence exposure: these include patient BMI, mAs, pitch, and radiation reduction protocols to name a few. As the number of slices increase with CTPA exposure does increase.

CHART 3: CHRONIC PE

	SENS	SPEC
CTPA	51	
V/P SPECT	93-97	90

CHART 4: PREGNANCY

	CTPA	V/P SPECT
Breast Exposure	10-70 mGy	less than 1.5 mGy
Fetal Exposure	less than 1.0 mGy	less than 1.0 mGy
Adverse reactions	Possible	None

Conclusions

In situations of Acute PE, Chronic PE, Pregnancy, Pediatrics, and the COPD population one can consider V/P SPECT, with or without low dose CT, as a first line investigation due to high sensitivity and specificity, low radiation, and no adverse reactions.

In situations of Pregnancy and Pediatrics due to the low likelihood of ventilation co-morbidities one could consider Perfusion only SPECT as a first line investigation. If co-morbidities exist then a full V/P SPECT should be performed. Also, V/P SPECT is not influenced by vascular volume changes during pregnancy as is CTPA.

In situations of COPD up to 31% of patients may have PE and up to 10% may die. Even those patients who have abnormal Chest X ray can still undergo V/P SPECT and in selected patients, V/P SPECT with low dose non-contrast CT could be considered. Technegas is considered the agent of choice in this population as there is less central airway deposition, better peripheral penetration, and it does not wash out as quickly as traditional aerosols.

List of Acronyms Used In The Present Document

COPD	Chronic Obstructive Pulmonary Disease
EANM	European Association of Nuclear Medicine
FOV	Field of View
ICRP	International Commission on Radiological Protection
LEAP	Low Energy All-Purpose
LEHR	Low Energy High Resolution
MDCT	Multi-Detector Computed Tomography
MD-CTPA	Multirow-Detector Computed Tomographic Pulmonary Angiography
OSEM	Ordered-Subset Expectation Maximization
PE	Pulmonary Embolism
PIOPED	Prospective Investigation of Pulmonary Embolism Diagnosis
SPECT	Single Photon Emission Computed Tomography
SPECT-CT	Single Photon Emission Computed Tomography—X-ray Computed Tomography
V/P SPECT	Ventilation/Perfusion Single Photon Emission Computed Tomography

REFERENCES:

1: Prospective evaluation of the negative predictive value of VQ SPECT using ^{99m}Tc-Technegas: Nucl Med Commun Aug:28(8):667-72

2: Ventilation/Perfusion SPECT for the diagnosis of pulmonary embolism in clinical practice; J Intern Med 2008 Oct:264(4)379-87

3: Radiation Dosimetry and Safety Issues in the investigation of Pulmonary Embolism: Seminars in Nuclear medicine: 40(6): November 2010:442-454

4: ventilation/Perfusion SPECT lung scintigraphy and computed tomography pulmonary angiography in patients with clinical suspicion of pulmonary embolism: Rev Esp Med Nucl Imagen Mol 2016 Jul-Aug; 35(4):215-20

5: Identifying the heterogeneity of COPD by V/P SPECT: a new tool for improving the diagnosis of parenchymal defect and grading the severity of small airways disease: DOVEPRESS 26 May 2017 Volume 2017:12 pages 1579-1587

6: Overview of the Novel and Improved Pulmonary Ventilation-Perfusion Imaging Applications in the Era of SPECT/CT: AJR December 2016; Volume 207 (6) 1307-1315

7: V/Q Scanning Using SPECT and SPECT/CT J Nucl Med September 1,2013 vol 54 no. 9 1588-1596

8: SPECT in Acute Pulmonary Embolism J Nucl Med December 2009 vol 50 no 12 1999-2007

LINKS TO EANM 2009 GUIDELINES FOR VENTILATION/PERFUSION SCINTIGRAPHY

https://eanm.org/publications/guidelines/gl_pulm_embolism_part1.pdf

https://eanm.org/publications/guidelines/gl_pulm_embolism_part2.pdf

CANM ACMN
The Canadian Association of Nuclear Medicine
Association canadienne de médecine nucléaire

P.O. Box 4383, Station 'E', Ottawa, Ontario, K1S 2L0
Tel.: **(613) 882-5097** Email: **canm@canm-acmn.ca**
Website: **www.canm-acmn.ca**